

Acceleration of Wound Healing Process Using Lactoferrin by Stimulating Proliferation of Fibroblasts in Wistar Rats (*Rattus Novergicus*): In Vivo Method

Shabilla Azzahra Khoirunnisa *^{ID}, Istiati Soepribadi^{ID}

Faculty of Dentistry, Institut Ilmu Kesehatan Bhakti Wiyata, Kediri, 64114, Indonesia

*Author: shabillaazzahra24@gmail.com

ARTICLE INFO

Article history:

Received 25 May 2023

Revised 23 November 2023

Accepted 23 November 2023

Available online 22 December 2023

E-ISSN: [2615-854X](#)

P-ISSN: [1693-671X](#)

How to cite:

Khoirunnisa SA, Soepribadi I. Acceleration of wound healing process using lactoferrin by stimulating proliferation of fibroblasts in wistar rats (*Rattus novergicus*): In Vivo method. Dentika Dental Journal. 2023; 26(2): 129-135

ABSTRACT

Wound is disruptions in the uniformity of body tissue structure, including the outermost layer from the skin to the internal organs, parts of fat, muscles, bones, and others. To address this issue, lactoferrin is a bioactive compound with promising benefits, playing a crucial role in wound healing by enhancing fibroblasts migration and proliferation, as well as collagen synthesis. Moreover, when used in wound therapy, lactoferrin induces a decrease in pro-inflammatory cytokines production by macrophages with an increase in the expression of VEGF and FGF-2. This study aimed to determine the role of lactoferrin in accelerating *in vivo* incision wound healing in Wistar rats and to prove the correlation between fibroblasts and collagen. This study adopted a laboratory experimental design using a post-test only control group with 28 samples. The samples were divided into the control, and three experimental groups, each treated with two drops of Lactoferrin (*Shaner Whey Protein*) at 20 mg/ml, 40 mg/ml, and 80 mg/ml. Each sample was observed for an increase in fibroblasts proliferation and density of collagen fibers. Lactoferrin concentration of 80 mg/ml had the most effect on increasing the number of fibroblasts and collagen with a significant value > 0.05 , using a posthoc test. Lactoferrin concentration of 80mg/ml showed the most significant results, showing a significant acceleration in wound healing process.

Keywords: Collagen; Fibroblasts; Lactoferrin; Wound; Wound healing

ABSTRAK

Luka adalah hilangnya keseragaman susunan jaringan tubuh yang meliputi bagian yang paling terluar dari lapisan kulit hingga organ bagian dalam tubuh, bagian-bagian lemak dan juga otot serta bahkan tulang beserta susunan lainnya di dalam tubuh. Laktoferin adalah salah satu senyawa bioaktif yang memberikan manfaat menjanjikan dalam bidang kesehatan. Laktoferin berperan dalam penyembuhan luka karena dapat meningkatkan migrasi dan proliferasi fibroblas serta sintesis kolagen. Pemberian laktoferin pada luka menginduksi penurunan produksi sitokin proinflamasi oleh makrofag dan peningkatan ekspresi VEGF dan FGF-2 yang membantu dalam penyembuhan luka. Mengetahui peran dan perbedaan laktoferin terhadap penyembuhan luka insisi secara *in vivo* pada Tikus Wistar dan membuktikan adanya korelasi antara fibroblas dan kolagen. Penelitian eksperimental laboratorium dengan desain posttest only control group design dengan jumlah sampel sebanyak 28 orang yang dibagi dalam kelompok kontrol, Dua tetes Laktoferin (*Shaner Whey Protein*) konsentrasi 20 mg/ml, 40 mg/ml dan 80 mg/ml. Setiap sampel diamati peningkatan proliferasi fibroblas dan kepadatan serat kolagen **Hasil:** Pemberian laktoferin pada konsentrasi 80 mg/ml paling berpengaruh dalam peningkatan jumlah fibroblasts dan kolagen dengan nilai signifikan (p) > 0.05 menggunakan uji *Post-Hoc*. Laktoferin sebesar 80mg/ml menunjukkan hasil paling signifikan dan terjadi percepatan proses penyembuhan luka.

Keyword: Kolagen; Fibroblas ; Laktoferin; Luka; Peyembuhan Luka



This work is licensed under a Creative Commons Attribution-ShareAlike 4.0 International.

<http://doi.org/10.32734/dentika.v26i2.12081>

1. Introduction

Wound is disruptions in the uniformity of the body tissue composition, including the outermost layer from the skin to the internal organs due to intentional or unintentional injury from outside the body [1]. Globally, there is a continuous increase in the daily incidence of injuries, both new and recurrent cases [2]. Aleksandra *et al.* (2014), found that the prevalence of injuries to the oral mucosa was approximately, where 95% are odontogenic infections in the facial space area [3]. Periodontal abscess contributes to 70% of problems presenting asperiapical inflammation. This is a significant concern as it shows an increased disruption in wound healing process, leading to a prolonged inflammatory phase and affecting the expected time [3].

Rahman *et al.* (2007) stated that lactoferrin is a protein subfraction of *whey* (milk residue produced in cheese production), characterized by antiviral, antibacterial, and anticancer activities, regulating the body immune system [4–6]. Additionally, lactoferrin stimulates wound healing factors during trauma/injury by increasing fibroblasts migration and proliferation. Fibroblasts play a crucial role in increasing collagen levels, initiating fibroblasts phase, promoting epidermal proliferation in wound, and the production of growth factors [7]. Therefore, this study aimed to investigate the role of lactoferrin in incision wound healing in Wistar rats at a concentration of 20, 40, and 80 mg/ml using *post-test only control group design* method.

2. Methods and Materials

This study has received approval from the Research Ethical Commission of Bhakti Wiyata Institute of Health Science Kediri numbered:135/FKG/EP/I/2023. This study adopted a laboratory experimental design using a post-test only control group with a sample size of 28 Wistar rats. The samples were divided into 4 groups, namely negative control, and three experimental groups comprising treatment 20%, 40%, and 80% lactoferrin, respectively. The inclusion criteria were male rats aged 2-3 months, weight 200- 250 grams, active, healthy fur, clear eyes, and absence of injuries or infections. Meanwhile, Wistar rats that died before being given treatment and those showing aggressive behavior were excluded.

The equipment used in this study included weight scales, laboratory standard glass apparatus, test tubes (*Pyrex, Japan*), stopwatch, surgical scissors, scalpel no 15 (*OneMed*), periodontal probe (*BPCP2, OsungMND, Korea*), micro brush, slide, gloves, light microscope (*Nikon H600L*) and digital camera (*Nikon DSFi2 300MP*). Experimental animals used were Wistar rats, provided by the Biochemical Science Laboratory, Faculty of Medicine, Airlangga University, Surabaya. Rats were fed with standard experimental animal food and water. Lactoferrin (*Shaner Whey Protein*), materials for fibroblasts and collagen preparations, including hematoxylin- eosin (HE) were obtained from Pathology Laboratory, Faculty of Medicine, Airlangga University, Surabaya. Furthermore, aniline blue solution and phosphotungstic acid (PTA), acetic acid, ketamine, xylazine, ether, distilled water, 10% neutralized buffered formaldehyde (NBF), bovine fixation solution, formalin, various concentrations of alcohol, xylol, liquid paraffin, and acetic acid were provided by Biochemical Science Laboratory, Faculty of Medicine, Airlangga University, Surabaya.

This study was approved by the study ethical committee of Bhakti Wiyata Institute of Health Science Kediri (135/FKG/EP/I/2023). Experimental animals were divided into four groups and adapted for seven days with adequate food and water. The anterior gingiva of rats mandible was incised using a scalpel under local anesthesia. Subsequently, two drops of Lactoferrin were given using a micro brush on the incision wound to the treatment group of 20, 40, and 80 mg/ml, respectively. The negative control group received no lactoferrin, while all animals were euthanized and decapitated on the 3rd day. Gingival mucosal biopsies of animal wound was placed in NBF 10% and fixed using a bovine solution for 24 hours. The specimens were embedded and subjected to Hematoxylin-Eosin to visualize fibroblasts and Masson Trichrome (MT) staining to identify collagen.

Fibroblasts were counted using a light microscope (*Nikon H600L microscope; Nikon, Japan*) at 400× magnification (*DS Fi2 300MP digital camera; Nikon*) capturing five views. Collagen density was observed using an *OLYMPUS E51 series microscope with a digital camera DP 12 (Japan)* at 400x magnification. Calculations of collagen were carried out using software (software) *NIS with BR elements installed on a Nikon Eclipse Ci microscope kit with a Nikon DS Fi2 digital camera*. Data normality was assessed with the Kolmogorov-Smirnov test and the homogeneity test was determined using the Levene test. A comparison test on normally distributed data was compared using the One Way ANOVA test. When data were not normally distributed, a comparison test was performed with the Kruskal-Wallis test. The significance test was carried

out through Post-Hoc analysis through the Mann-Whitney test. Subsequently, correlation test was carried out using the Spearman test to determine the relationship between fibroblasts and collagen.

3. Results

The data were obtained by analyzing hematoxylin-eosin staining of fibroblasts and collagen cells on the 3rd day after the incision treatment. The staining images were observed using a light microscope with 400x magnification. During histological examination with Hematoxyli-Eosin, microscopic inflammation was observed in fibroblasts proliferation treatment as presented in Figure 1.

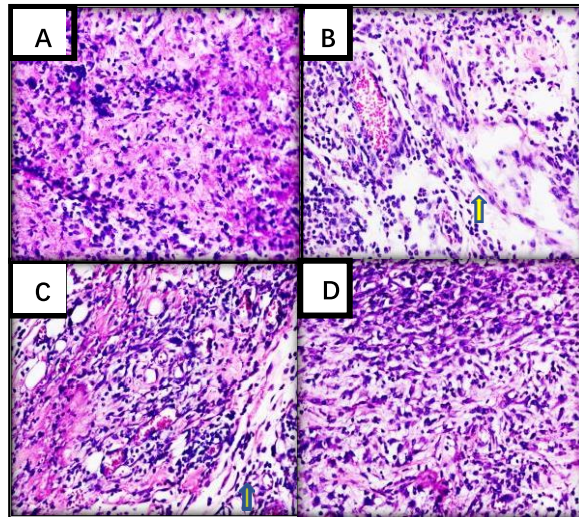


Figure 1. Hematoxyllin-Eosin staining of fibroblasts. (A) The control group (B-D). Treatment groups of 20, 40, and 80 mg/ml lactoferrin, respectively. Hematoxylin (violet color) was used as a nuclear staining of fibroblasts. Eosin (red/pink color) for fibroblasts staining. Yellow arrow showed fibroblasts cells. The picture was captured with 400X magnification.

Furthermore, histological examination with MT staining showed microscopic areas of inflammation for collagen quantification based on the scoring, as presented in Figure 2.

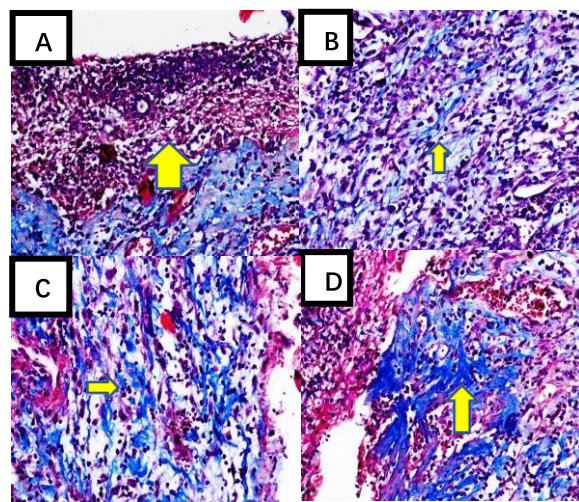


Figure 2. MT Microscopic Image. (A). The area of inflammation in the Treatment Total collagen score 0; (B). Treatment area Total collagen score 1; (C). Treatment area Total collagen score 2; (D). Treatment area Total collagen score 3. Hematoxylin (violet color) was used as a nuclear staining of fibroblasts. Eosin (red/pink color) for fibroblasts staining. Yellow arrow showed fibroblasts cells. The picture was captured with 400X magnification.

The One-way ANOVA test results showed a significant effect of lactoferrin concentration on fibroblasts. The results showed a significant coefficient = 0.000 < 0.05, leading to a further test (post hoc) to determine the difference in the effect of each treatment group.

The Duncan test was carried out to determine significant differences in the treatment groups without neglecting the number of treatments available. For accuracy maintenance, the significant coefficient value must be < 0.05, showing significant differences among data groups in each treatment. The results showed that the control and treatment groups significantly affected each other.

Table 1. Effect of Lactoferrin administration on fibroblasts count in the control group, 20 mg/ml, 40 mg/ml, and 80 mg/ml

Group	Lactoferrin Concentration	<i>p</i>
Lactoferrin	Control	0.000
	20 mg/l	
	40 mg/l	
	80 mg/l	

Description: *significant (p<0.05)

Table 2. Different effect of Lactoferrin administration on fibroblasts count in the control group, 20 mg/ml, 40 mg/ml, and 80 mg/ml

Group	Lactoferrin	<i>p</i>
Control	20 mg/l	0.000
	40 mg/l	
	80 mg/l	
20 mg/l	Control	
	40 mg/l	
	80 mg/l	
40 mg/l	Control	
	20 mg/l	
	80 mg/l	
80 mg/l	Control	
	20 mg/l	
	40 mg/l	

Description: *significant (p<0.05)

The One-way ANOVA test results showed a significant effect of lactoferrin concentration on collagen, with a coefficient = 0.000 < 0.05. Consequently, a further test (*post-hoc*) was carried out to determine the difference in the effect of each treatment group.

The Duncan test was carried out to determine significant differences in the treatment groups without neglecting the number of treatments available. For accuracy maintenance, the significant coefficient value must be < 0.05, showing significant differences among data groups in each treatment. The test results showed that the control and treatment lactoferrin 20, 40, and 80 mg/ml had a different effect between groups.

Table 3. Effect of Lactoferrin administration on collagen count in the control group, 20 mg/ml, 40 mg/ml, and 80 mg/ml

Group	Lactoferrin Concentration	<i>p</i>
Lactoferrin	Control	0.000
	20 mg/l	
	40 mg/l	
	80 mg/l	

Description: *significant (p<0.05)

Table 4. Different effect of Lactoferrin administration on collagen count in the control group, 20 mg/ml, 40 mg/ml, and 80 mg/ml

Group	Lactoferrin Concentration	p
Control	20 mg/l	0.000*
	40 mg/l	
	80 mg/l	
20 mg/l	Control	0.016
	40 mg/l	
	80 mg/l	
40 mg/l	Control	0.072
	20 mg/l	
	80 mg/l	
80 mg/l	Control	0.000*
	20 mg/l	
	40 mg/l	

Description: *significant (p<0.05).

Based on the correlation test using the Spearman test, the results showed that fibroblasts and collagen had a positive and significant correlation. This was shown by a correlation coefficient = 0.914 (with a very high degree of correlation), as presented in Table 5.

Table 5. Correlation between fibroblast and collagen on acceleration of wound healing process

Fibroblasts	Correlation Coefficient	Collagen
	p	0.914**

Description: *significant (p<0.01)

4. Discussions

Lactoferrin plays a crucial role in wound healing by enhancing the migration and proliferation of fibroblasts. Moreover, fibroblasts contribute to increased collagen production, as showed by the combination of three-chain proteins forming the main elements of the external wound matrix which helps healing of scar tissue. In this study, high lactoferrin concentration, with the highest fibroblasts amount was found at 80mg/ml. Meanwhile, the lowest number of fibroblasts and collagen was observed in the negative control group. The result was consistent with Istiati et al.(2019), where lactoferrin concentration of 40g/ml enhanced the ability to heal gingival wound by increasing FGF-2 and VEGF [8,9]. Lactoferrin is capable of binding to Receptors for Advanced Glycation End Products (RAGE) on macrophage cell surfaces, suppressing Reactive Oxygen Species (ROS) production and inhibiting NFκB activation [10,11]. However, disrupted NFκB activation led to decreased pro-inflammatory cytokine production, increased VEGF expression, and high FGF-2 expression, accelerating the gingival wound healing process [12,13].

The impact of Lactoferrin on wound healing includes the stimulation of TNF-α and IL-8 cytokines. TNF-α produced by macrophages and stimulates IL-8 production through keratinocytes and superoxide activation by endothelial cells. This effect results in increased production of VEGF by endothelium and FGF-2 through keratinocytes [14,15], leading to an increase in the proliferative phase of wound healing. In this process, fibroblasts play a significant in preparing the healing phase protein. Interleukin-1b (IL-1b), platelet-derived growth factor (PDGF), and fibroblasts growth factor (FGF) production are stimulated by proliferation of fibroblasts [16,17]. Generally, fibroblasts are found in the inflammatory or injured phase, actively producing extracellular matrix. During the inflammatory phase of wound healing, PDGF secreted by macrophages contributes to stimulating the release of collagenase by fibroblasts, which plays an important role in tissue repair [18,19].

In this study, the administration of lactoferrin accelerated the healing process of wound [20]. Matrix Metalloproteinase (MMP-12) showed effective coordination, where fibroblasts degraded the fibrin matrix and

replaced it with glycosaminoglycan (GAGS). After the healing process, the cellular matrix was replaced by type III collagen, produced through fibroblasts [21].

5. Conclusions

In conclusion, this study showed that the administration of lactoferrin accelerated wound healing process by stimulating proliferation of fibroblasts cells. The increased number of fibroblasts cells correlated with an augmentation in fibroblasts participating in collagen synthesis, which contributed to scar tissue closure.

6. Acknowledgment

The authors have nothing to acknowledge.

7. Conflicts of Interest

The authors stated there is no conflict of interest.

References

- [1] Primadina N, Basori A, David S. Penyembuhan luka ditinjau dari aspek mekanisme seluler dan molekuler 2019. *Qanun Medika* 2019;3(1).
- [2] Diligence M. Advanced medical technologies. <<http://mediligence.com>> (23 March 2023)
- [3] Aleksandra W, Hendrich B, Nienartowicz J, Guziński M, Szaśiadek M. Odontogenic inflammatory processes of head and neck in computed tomography examinations. *Pol J Radiol*. 2014; 24(79): 431–8.
- [4] Monuteaux MC, Fleegler EW, Lee LK. A cross-sectional study of emergency care utilization and associated costs of violent-related (assault) injuries in the United States. *J Trauma Acute Care Surg*. 2017; 83(2): 310–31.
- [5] Al-Baarri AN, Legowo AM, Siregar RF, et al. Teknik pengambilan enzim dari berbagai sumber. 2nd Ed., Semarang: Indonesian Food Technologist, 2016.
- [6] Budiyanto C, Kanetro B, Luwihana S. Potensi senyawa bioaktif susu sapi dan kacang-kacangan lokal sebagai bahan pangan fungsional. *J Ilmiah Mahasiswa Agribisnis UNS*. 2021; 5(1): 953–64.
- [7] Hariani L. Pola proses penyembuhan luka sekitar melalui analisis ekspresi EGF, VEGF, TGF-beta, kolagen, MMP- 1 dan pembuluh kapiler yang diinduksi adiposed derived mesenchymal stem cells pada luka primer. Dissertation. Surabaya: Program Pasca Sarjana Ilmu Kesehatan UNAIR, 2017.
- [8] Saifurrijal M. Potensi laktoferin dalam menghambat kolonisasi *C glabrata*. Skripsi. Surabaya: Program Pendidikan Dokter Gigi FKG UNAIR, 2015.
- [9] Istiati NI, Surjono I, Surboyo M. Role of lactoferrin fibroblast growth factor 2 and vascular endothelial growth factor in gingival wound. *JKIMSU* 2019; 8(3).
- [10] Nita M, Grzybowski A. The role of the reactive oxygen species and oxidative stress in the pathomechanism of the age-related ocular diseases and other pathologies of the anterior and posterior eye segments in adults. *Oxid Med Cell Longev*. 2016; 3164734.
- [11] Hadian I, Alfianto U, Arianto AT. Ketotifen mempengaruhi jumlah fibroblas dan kepadatan sel kolagen luka insisi tikus wistar. *CDK-261* 2018; 45 (2): 90-93.
- [12] Handy A, Widodo MA. Peranan stres oksidatif pada proses penyembuhan luka. *J Ilmiah Ked Wijaya Kusuma*. 2019; 5(2): 22–9.
- [13] Az-Zahra S, Hidayah SA, Aini SN, Yuniarni A, et al. Potensi senyawa ekstrak dari carica pubescens terhadap penyembuhan luka insisi gingiva: Melalui mekanisme proliferasi, differensiasi dan immunorespon. *Med Health J* 2021; 1(1): 11-21
- [14] Landén NX, Li D, Ståhle M. Transition from inflammation to proliferation: a critical step during wound healing. *Cell Mol Life Sci*. 2016; 73(20): 3861-85.
- [15] Kim C, Son K, Choi S, Kim J. Human lactoferrin upregulates expression of KDR/Flk-1 and stimulates VEGF-A-mediated endothelial cell proliferation and migration. *FEBS Lett* 2016; 580(18): 4332–6.
- [16] Sudarminto MS. Potensi Laktoferin terhadap peningkatan jumlah sel fibroblas dan kolagen pada proses penyembuhan luka sayat tikus wistar (In Vivo). Skripsi. Surabaya: Program Pendidikan Dokter Gigi FKG UNAIR, 2018.
- [17] Nugu RHF. Uji Potensi ekstrak daun binahong (*Anredera cordifolia* (ten) steenis) terhadap jumlah fibroblas dan ketebalan kolagen pada luka bakar tikus wistar. Skripsi. Surabaya: Program Studi S1 Fakultas Farmasi UKWMS, 2018;

- [18] Berlanga-Acosta J, Gabilondo-Cowley J, Barco-Herrera D, Martín-Machado J, Guillen-Nieto G. Epidermal growth factor (EGF) and platelet-derived growth factor (PDGF) as tissue healing agents: clarifying concerns about their possible role in malignant transformation and tumor progression. *J Carcinogene Mutagene*. 2015; 2(1): 100–5.
- [19] Rustiasari UJ. Proses penyembuhan cedera jaringan lunak muskuloskeletal. *JORPRES* 2017; 13:43–53.
- [20] Takayama Y, Aoki R. Roles of lactoferrin on skin wound healing. *Biochem Cell Biol*. 2014; 90(3): 306.
- [21] Harlim A. Buku ajar ilmu kesehatan kulit dan kelamin imunologi inflamasi. Jakarta: Fakultas Kedokteran UKI, 2018.