

Traumatic Ulcer Associated with Iatrogenic Trauma After Basal Cell Adenoma Surgery

Fitri Dona Siregar*^{}, Riani Setiadhi^{}

Department of Oral Medicine, Faculty of Dentistry, Universitas Padjadjaran, Bandung, 40161, Indonesia

*Author: fitri20012@mail.unpad.ac.id

ARTICLE INFO

Article history:

Received 25 May 2023

Revised 23 November 2023

Accepted 23 November 2023

Available 22 December 2023

E-ISSN: [2615-854X](#)

P-ISSN: [1693-671X](#)

How to cite:

Siregar FD, Setiadhi R. Traumatic ulcer associated with iatrogenic trauma after basal cell adenoma surgery. Dentika Dental Journal 2023; 26(2): 07-12.

ABSTRACT

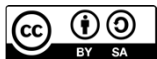Traumatic ulcer is an oral cavity lesion characterized by loss of epithelial lining, reaching the lamina propria. This condition presents a single lesion with irregular borders, surrounded by diffuse erythema, and covered with pseudo-membrane. In specific case, the traumatic ulcer was caused by iatrogenic trauma after basal cell adenoma surgery. This case report aimed to discuss the causes of traumatic ulcer. A 39-year-old female was referred to the Oral Medicine Clinic from the Ear, Nose, and Throat Department, complaining of pain in the oral mucosa after basal cell adenoma surgery. On extraoral examination, the facial symmetry was intact along with dry and exfoliative lips. A solitary, oval, yellowish-white intraoral ulcer covered with pseudomembrane, irregular borders surrounded by diffuse erythema on the palate, left buccal mucosa and upper labial mucosa was present. The patient was diagnosed with traumatic ulcer due to iatrogenic trauma after surgery for basal cell adenoma located within the parotid gland that extended to the left palate. The treatment administered comprised instructions to clean the oral cavity using gauze and a cotton stick soaked in 0.2% chlorhexidine gluconate. Additionally, compressing the affected areas with gauze soaked in 0.9% NaCl and applying a thin coating of Vaseline album on the lips were part of the therapeutic measures. Given the iatrogenic nature of traumatic cancer, comprehensive therapy was considered essential to prevent secondary infection and address issues related to speech, appearance, and masticatory functions.

Keywords: Basal Cell Adenoma ; Iatrogenic ; Trauma; Traumatic Ulcer; Surgery

ABSTRAK

Ulser traumatik adalah salah satu lesi rongga mulut yang ditandai dengan hilangnya lapisan epitel sampai lamina propria, tunggal, tepi iregular yang dikelilingi eritema difus dan ditutupi dengan pseudo-membran. Penyebab terjadinya ulser traumatik pada laporan kasus ini karena trauma iatrogenik pasca bedah adenoma sel basal. Laporan kasus ini bertujuan untuk membahas penyebab terjadinya ulser traumatik. Seorang perempuan berusia 39 tahun di rujuk oleh Departemen Telinga, Hidung dan Tenggorokan ke Klinik Penyakit Mulut dengan keluhan sakit pada mukosa mulut pasca bedah adenoma sel basal. Ekstra oral tampak wajah simetris disertai dengan bibir kering dan eksfoliatif. Intra oral terdapat ulser tunggal berwarna putih kekuningan yang ditutupi pseudomembran, oval, tepi iregular yang dikelilingi eritema difus pada palatum, mukosa bukal kiri dan mukosa labial atas. Diagnosis pasien ini adalah ulser traumatik akibat trauma iatrogenik pasca bedah adenoma sel basal pada kelenjar parotis yang meluas sampai palatum kiri. Terapi yang diberikan adalah instruksi membersihkan rongga mulut menggunakan kasa dan kapas lidi yang dibasahi chlorhexidine gluconate 0,2%, serta kompres menggunakan kasa yang dibasahi NaCl 0,9 % dan mengoles tipis vaselin album pada bibir. Ulser traumatik pada pasien ini akibat dari trauma iatrogenik pasca bedah adenoma sel basal sehingga diperlukan terapi komprehensif untuk mencegah terjadinya infeksi sekunder dan mengatasi masalah terkait bicara, penampilan, dan fungsi pengunyahan.

Keyword Adenoma Sel Basal; Iatrogenik; Trauma; Ulser Traumatik; Pembedahan



This work is licensed under a Creative Commons Attribution-ShareAlike 4.0 International.

<http://doi.org/10.32734/dentika.v26i2.12115>

1. Introduction

Traumatic ulcer is an oral lesion characterized by the loss of epithelial lining, reaching the lamina propria. This condition presents a single lesion with irregular borders surrounded by diffuse erythema, white in color, and covered with pseudo-membrane [1–6]. Traumatic ulcer can be acute, chronic, self-limiting, and typically heals within 10-14 days when the causative factor is eliminated [1,4,5]. The symptoms are manifested frequently on the lips, palate, lateral tongue, as well as buccal mucosa. Lesions can occur in other areas including the mucobuccal folds and gingiva due to trauma from toothbrushes or food [1,3,4,7,8].

In Indonesia, traumatic ulcer has a prevalence of 93.3%, which is the highest compared to Thailand (13.2%), Malaysia (12.4%), Spain (7.1%), Denmark (4.4%) and Chile (3.5%). This condition is predominantly found in males (20.9%) than in females (13.7%), possibly due to the greater biting force, leading to mucosa ulceration [4,5,8–10]. Traumatic ulcer can be a consequence of damage from thermal, physical, chemical, and iatrogenic trauma, as well as the formation of ulcer at the mucous membranes. Iatrogenic trauma might occur in the oral mucosa during dental treatment using dry cotton rolls, saliva ejectors, rotary instruments, and dental tools [3,4,7,10].

According to the World Health Organization (WHO), basal cell adenoma is a rare benign tumor composed of basaloid cells with a structure resembling a basement membrane but lacking a myxochondroid stroma component [11–13]. It was first defined in 1967 by Kleinsasser and Klein in 1967 as a monomorphic adenoma subtype [12,14]. Only 1-2% of salivary gland tumors are considered a part of these benign neoplasms, and women outnumber men by a ratio of 2:1. The parotid gland has the highest prevalence (75%) compared to the submandibular glands (5%) and the small salivary glands of the upper lip (6%) [11–14].

Histopathological picture of a basal cell adenoma biopsy obtained by the Anatomical Pathology Department showed pieces of tumor mass tissue consisting of round, oval, small to medium-sized cells with few cytoplasm growing hyperplastically. These cells are partially grouped to form glands and trabeculae, solid with palisading at the edges. The lumen contains an eosinophilic mass, the nucleus is monotonous, pale, and mitoses rarely occur. The connective tissue stroma is partially hyalinized and myxomatous degenerated [11–14].

Traumatic ulcer in this patient occurred due to iatrogenic trauma after basal cell adenoma surgery, performed using the maxillary swing technique with skin incisions along Weber–Fergusson (Figure 1a-c). This surgical technique caused postoperative traumatic ulcer on the oral mucosa and upper lip [7,15].

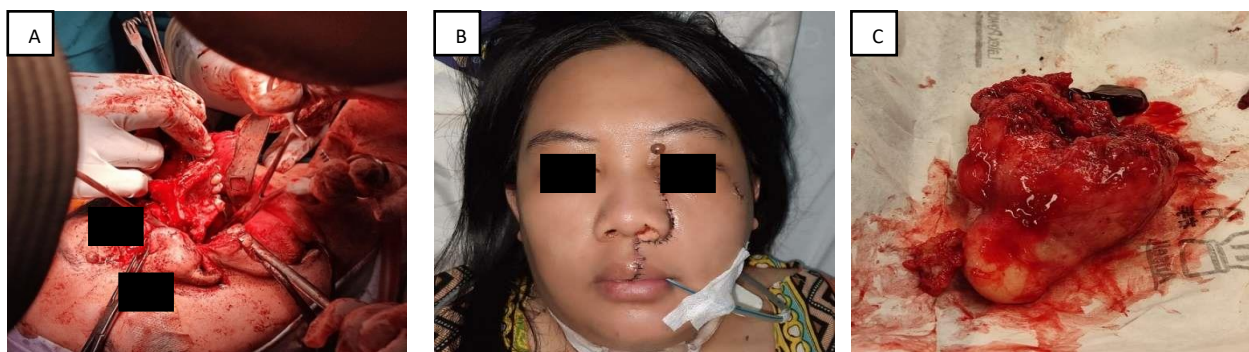

Figure 1. The maxillary swing technique with skin incisions along Weber–Fergusson (Figure 1a-c)

This case report aimed to discuss the causes of traumatic ulcer related to iatrogenic trauma after basal cell adenoma surgery.

2. Case Report

A 39-year-old female was referred from the Department of Ear, Nose, and Throat (ENT) to the Oral Medicine Clinic with a chief complaint of pain in the oral mucosa after basal cell adenoma surgery. The patient was on a liquid diet given through an Orogastric Tube (OGT) due to difficulty in widely opening the mouth. The presence of a tumor with a diameter of approximately 1 cm was observed on the palate three years ago

which had progressively increased in size. The tumor caused various symptoms, including a nasal sound, occasional left nasal obstruction, snoring during sleep, shortness of breath, and difficulty in swallowing, though without any impact on the left ear. There was no history of hypertension, diabetes mellitus, weight loss, contact with COVID-19 patients, and recurrent oral thrush. The ENT Department performed a tumor biopsy, which was subsequently sent to the Anatomical Pathology Department in January 2022. The diagnosis, based on the results of the biopsy, was a basal cell adenoma in the parotid gland extending to the left palate. Tumor surgery was performed by the ENT Department in May 2022 and five days later, the patient was referred to the Oral Medicine Clinic.

Upon extraoral examination, the face was symmetrical, there was a stoma gauze covering the postsurgery wound, lymph nodes could not be assessed, a neck tracheostomy tube was attached, and OGT passed through the oral cavity (Figure 2a). The lips looked dry with exfoliative and sutures (Figure 2b), while an oval, solitary, yellowish-white ulcer covered with pseudomembrane 0.2x0.5 cm in size, irregular margin surrounded by diffuse erythema, and sutures on the upper labial mucosa was visible intraorally (Figure 2c). Furthermore, there were similar lesions on the left buccal mucosa and palate measuring 1 × 3 cm (Figure 2d) and 3 × 5 cm (Figure 2e) in size respectively. The diagnosis of this patient was traumatic ulcer resulting from iatrogenic trauma after surgery of a basal cell adenoma in the parotid gland that extended to the left palate.

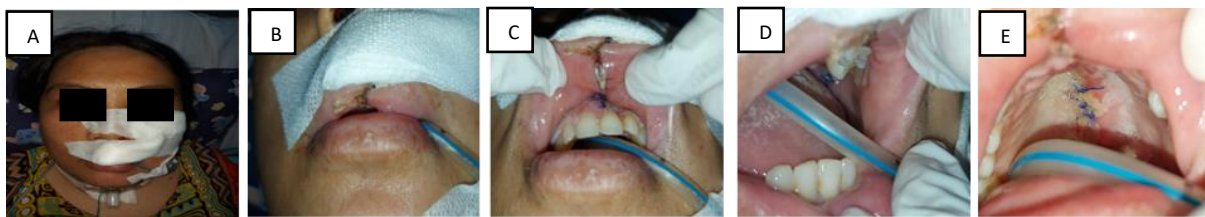


Figure 2. Clinical features at the first visit. (A) the face was symmetrical, a stoma gauze covering the wound after surgery, a tracheostomy tube was placed on the neck and OGT through the oral cavity; (B) the lips looked dry, exfoliative, and suture threads (C) a single oval ulcer covered with pseudomembrane, 0.2x0.5 cm in size on the upper labial mucosa (D) on the left buccal mucosa 1x3 cm in size; (E) on the palate 3x5 cm in size. (Personal documentation)

The treatment administered by The Oral Medicine Clinic included oral hygiene instructions, communication, information, and education for the patient to clean the oral cavity using a cotton swab soaked in 0.2% chlorhexidine gluconate. The lesions on the lips were compressed using gauze soaked in 0.9% NaCl and applying a thin layer of Vaseline album 3 times a day. The ENT department intravenously administered 2 grams of ceftriaxone once a day, 1 gram of paracetamol every 6 hours, and 500 mg of tranexamic acid every 8 hours.

Subsequent visits at first did not demonstrate any substantial improvement (Figure 3a-e) but after three weeks, the oral problems diminished and the patient regained the ability to fully open the mouth on the fourth visit. The medicine provided was consistently used, and the patient was referred to the Prosthodontics Clinic for the creation of an acrylic palate plate. This plate aimed to address issues related to speech, appearance, and masticatory functions [16].

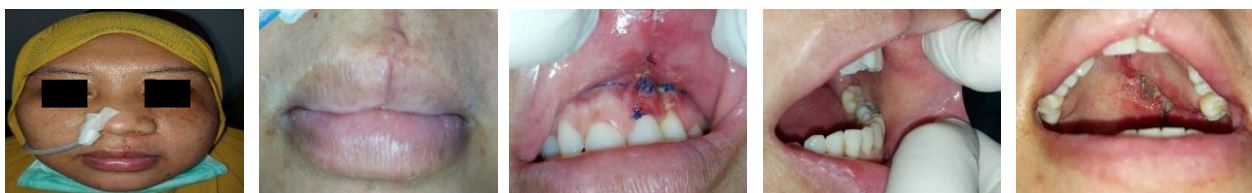

Figure 3. Clinical picture after 3 weeks of treatment. (A) symmetrical face, stoma gauze, tracheostomy removed, lymph nodes not palpable and painless, NGT tube; (B) dry lips, exfoliative, suture threads have fallen off; (C) a single, oval, yellowish-white pseudomembrane-covered ulcer on the upper labial mucosa has improved; (D) The buccal mucosa is repaired; (E) The palate has improved. (Personal documentation)

During the fifth visit after four weeks of treatment, extra oral scar tissue was found on the upper lip which extended to the philtrum, and the NGT remained attached through the nose (Figure 4a, b). Intraorally, there was scar tissue or suture threads (Figure 4c, d, e). The patient had no complaints after the insertion of the acrylic palate prosthesis (Figure 4f).

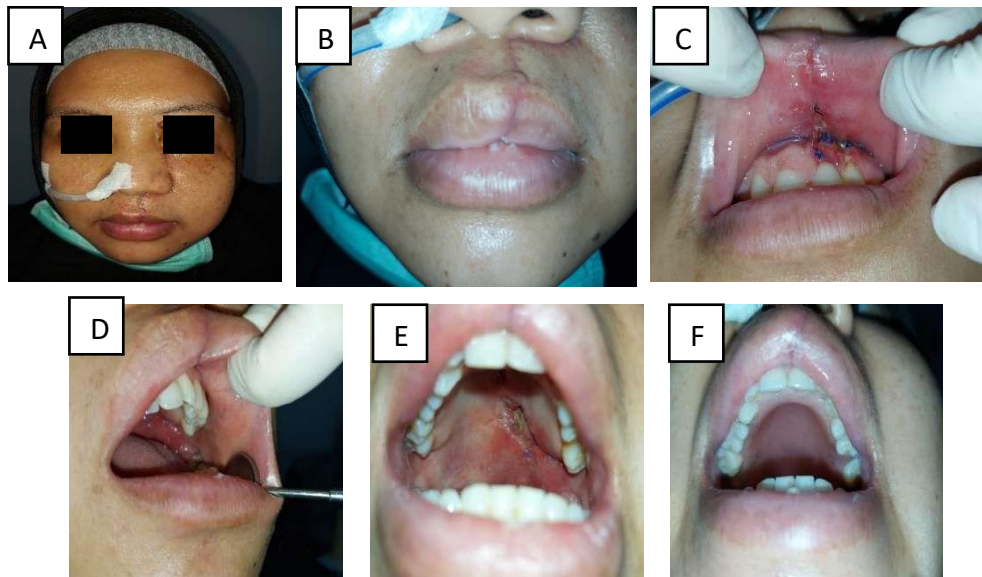


Figure 4. Clinical picture after 4 weeks of treatment. (A, B) scar tissue on the upper lip that extends to the philtrum, NGT inserted through the nose; (C, D, and E) upper labial mucosa, left buccal, and palate; (F) An acrylic plate prosthesis was used on the palate without any complaints. (Personal documentation)

3. Discussions

Commonly, ulcer in the oral cavity is a frequent cause for patients to seek dental care due to their painful nature. Acute and chronic traumatic ulcer can be distinguished clinically, with acute ulcer often painful and associated with a history of trauma, requiring consideration of differential diagnoses such as recurrent aphthous stomatitis and oral mucositis. Meanwhile, chronic ulcer is painless or mildly painful, sometimes with patients unaware of the trauma causes. Differential diagnoses include oral squamous cell carcinoma (OSCC) and infectious ulcer [1,3,10].

Traumatic ulcer is diagnosed by taking a complete anamnesis and identifying the causative factors of the trauma. Anamnesis is performed by asking for information such as the time of lesion appearance, duration, recurrence, number of lesions, history of trauma, and medical history including medications consumed and family history [5–7,10]

Iatrogenic trauma to the oral mucosa, which is inadvertently induced by a health practitioner is another factor contributing to traumatic ulcer. This type of trauma includes injuries from medical procedures such as intubation during general anesthesia, ENT surgery, endoscopic interventions, and failures that occur during invasive procedures [10]. It is important to understand that this harm is unrelated to the underlying disease being treated. Iatrogenic trauma can result in injury to the superficial tissues, including the skin and soft tissues, or to the deep tissues, namely the bones and tendons. These wounds fall under the scope of all hospital departments. Furthermore, the use of subcutaneous and deep artificial implants has led to increased iatrogenic wounds in surgical departments, particularly in the areas of cardiac, neurosurgery, orthopedics, and plastic surgery. These fields have experienced a rise in the use of biological materials, an expansion of surgical indications, and an increase in the age limit for surgery [17].

The Oral Medicine Clinic administers both non-pharmacological and pharmacological therapies. Non-pharmacological therapy eliminates causative factors such as sharp teeth restoration and replacement of broken fillings [3–5]. Meanwhile, pharmacological therapy includes the use of 0.2% chlorhexidine gluconate mouthwash, 0.9% NaCl, and vaseline album. Chlorhexidine gluconate mouthwash is indicated before and after

surgery for short and long-term maintenance of oral health. This mouthwash is also utilized as a fast-acting antimicrobial and antifungal. It effectively targets both aerobic and anaerobic bacteria, as well as RNA and DNA viruses [6,18]. NaCl is indicated in adults and children as a source of electrolytes and water for hydration and antiseptic. The inhibitory effect on bacteria growth occurs by reducing water activity and damaging cell membranes. This activity is attributed to the high concentration of sodium outside the cell, pulling the intracellular content and eventually leading to changes in the structure of the bacteria cell. Chlorine chemicals influence how cell membranes function, particularly in the transport of extracellular nutrients, carbohydrates, and amino acids [19,20]. Additionally, vaseline album is used as a protector to prevent dryness and peeling of the lips [21].

Ceftriaxone, tranexamic acid, and paracetamol were administered by the ENT department. Specifically, ceftriaxone is indicated for the treatment of *Neisseria gonorrhoeae* and *Salmonella typhi* infections [22], while paracetamol is an analgesic and antipyretic. Tranexamic acid is an anti-fibrinolytic agent often used to stop bleeding during major surgery [23,24]. Traumatic ulcer would have a good prognosis when diagnosed and treated early [5].

After 4 weeks of therapy at the Oral Medicine Clinic, the ulcer had improved, the patient could open the mouth widely and the suture threads had been detached slowly. Although the patient could drink using a straw, eating still required the use of NGT. Acrylic plate prosthesis was routinely utilized, and maintenance of oral hygiene was recommended. Based on the results of a biopsy performed at the Anatomical Pathology Department, the identified basal cell adenoma did not require radiotherapy. The ENT department advised to continue the evaluation until the NGT was removed.

4. Conclusions

In conclusion, the traumatic ulcer in this patient was due to iatrogenic trauma after basal cell adenoma surgery. Therefore, comprehensive therapy was needed to prevent secondary infection and address issues related to speech, appearance, and masticatory functions.

5. Acknowledgments

The authors are grateful to the patient for accepting to be a part of this case report.

6. Informed Consent

Written informed consent was acquired from the patient for the purpose of publishing this case report and any related photos. The Editor-in-Chief of this journal can review a copy of the written consent upon request.

7. Conflicts of Interest

The authors declare that there are no conflicts of interest to disclose concerning this study.

References

- [1] Ishaquddin S, Maya D, Ghadage M. Traumatic ulcer or squamous cell carcinoma of the tongue? : Case report. *Int J Healthc Biomed Res.* 2013; 2(1): 57–60.
- [2] Puspitasari D, Apriasari ML. Analysis of traumatic ulcer healing time under the treatment of the Maui banana (*Musa acuminata*) 25% stem extract gel. *Padjadjaran J Dent.* 2017; 29(1): 21–5.
- [3] Herawati E, Nur'aeny N. Etiologi, distribusi lokal, dan terapi ulser traumatik pada pasien di rumah sakit gigi dan mulut Universitas Padjadjaran. *Dent J Kedokt Gigi Univ Baiturrahmah.* 8(3): 313–9.
- [4] Selvi T, Ramani P. Incidence of traumatic ulcer among the patients visiting private dental hospital-retrospective study. *J Pharm Res Int.* 2021; 3(64A): 444–54.
- [5] Nalin DAS, Mary DJ, Leukose DT, Sreedhar DS, Padiath S. Traumatic Ulcer –Mimicking Squamous Cell Carcinoma. *J Dent Med Sci.* 2016; 15(3): 83–6.
- [6] Setiadhi R, Nelonda R. Management of chronic traumatic ulcer mimicking oral squamous cell carcinoma on the tongue. *Dent J.* 2018; 51(2): 76–80.
- [7] Koray M, Tosun T. Oral mucosal trauma and injuries. *Intechopen.* 2019; 1–18.

- [8] Anura A. Traumatic oral mucosal lesions: A mini review and clinical update. *OHDHM*. 2014; 13(2): 1–7.
- [9] Sa'adah N, Hendarti HT, Prehananto H, Soebadi B, Pertiwi EP, Adriansyah AA. The effect of basil leaves (*ocimum sanctum* l.) extract gel to traumatic ulcer area in *rattus norvegicus*. *J Kesehat Gigi*. 2020; 8(1): 11–5.
- [10] Herawati E, Theodora AD. Temuan klinis dan manajemen kasus ulserasi rongga mulut terkait trauma iatrogenik. *J Ked Gi Unpad*. 2019; 31(2): 102–7.
- [11] Prado RFD, Cardoso CL, Consolaro A, Taveira LAA. Pleomorphic adenoma versus basal cell adenoma: An immunohistochemical analysis with β -catenin. *Braz Dent Sci*. 2014; 17(1): 23–31.
- [12] Li BB, Zhou CX, Jia SN. Basal cell adenoma of salivary glands with a focal cribriform pattern: clinicopathologic and immunohistochemical study of 19 cases of a potential pitfall for diagnosis. *Ann Diagn Pathol*. 2014; 18: 5–9.
- [13] Abdeljelil NB, Masmoudi M, Thabet W, Bellalah A, Chebil E, Hasnaoui M, et al. Basal cell adenoma of the parotid gland: A rare entity. *Ear, Nose Throat J*. 2021; 0(0): 1–4.
- [14] Rajasenthil V, Ravi A. Basal cell adenoma of the parotid gland—A Rare Entity. *Indian J Surg*. 2013; 1–3.
- [15] Nomura T, Kishimoto M, Iwaki H, Ochi A, Kishimoto S. Maxillary swing approach for removal of palatal carcinoma: A modified procedure. *Case Rep Otolaryngol* 2018; 2018: 531207
- [16] Aditama P, Sugiatno E, Indrastuti M, Wahyuningtyas E. Protesa obturator definitif resin akrilik pada pasien systemic lupus erythematosus (SLE) pasca maksilektomi. *J Kedokt Gigi Univ Padjadjaran*. 2020; 32(1): 64–71.
- [17] Cheng B, Tian J, Peng Y, Fu X. Iatrogenic wounds: a common but often overlooked problem. *Burns & Trauma*. 2019; 7(18): 1–7.
- [18] Deus FP, Ouanounou A. Chlorhexidine in Dentistry: Pharmacology, Uses, and Adverse Effects. *Int Dent J*. 2022; 72: 269–77.
- [19] Braun B. 0.9% sodium chloride injection usp prescribing information. Bethlehem: USA, 2020; 1–10.
- [20] Rondhianto W, AI W. Perbedaan penggunaan povidone iodine 1% dengan NaCl 0,9% sebagai dekontaminasi oral terhadap kolonisasi staphylococcus aureus pada pasien post operasi dengan general anesthesia di ruang mawar RSUD DR. Abdoer Rahem Situbondo. *J Keperawatan*. 2015; 6(1): 27–43.
- [21] Altmeyer P. Vaseline. In: editors., editor. Altmeyers medical. Encyclopedia Springer; 2020.
- [22] Khan MY, Roy M, Bansal RRR, U.K. A review- Ceftriaxone for life. *J Pharm Res*. 2017; 7(1): 35–48.
- [23] Freo U, Valerio A. Paracetamol: A review of guideline recommendations. *J Clin Med*. 2021; 10(15): 1–22.
- [24] Arianto F, Ariffin MHM, Kamaruzaman E. Optimal dose of tranexamic acid to prevent bleeding and to decrease transfusion demand in adolescent idiopathic scoliosis patients undergoing operative treatment. *J Orthop dan Traumatol Indones*. 2018; 1(3): 32–6.