

COMPREHENSIVE ORTHODONTIC TREATMENT OF PALATALLY IMPACTED MAXILLARY CANINES

(PERAWATAN ORTODONTI KOMPREHENSIF KASUS IMPAKSI KANINUS DI REGIO PALATAL)

Ervina Sofyanti

Department of Orthodontic
Faculty of Dentistry, University of Sumatera Utara
Jl. Alumni No. 2, Kampus USU, Medan-20155

Abstract

Comprehensive orthodontic treatment among adult patients that required multidisciplinary approaches has been increased since a lot of them could not avail themselves with any treatment decades ago. Treatment of impacted canine in adult orthodontic patient needs to be integrated into the overall orthodontic treatment scheme. The following case report described an orthodontic treatment of 33-year-old woman with convex profile, palatally impacted of left maxillary canines and single dental crossbite. Dental midline shift associated with narrow arch form of upper arch and asymmetric tooth amount. Management of this case was started by extraction of first upper premolars in the opposite site from impacted maxillary in order to overcome dental discrepancy problem. Surgical exposure allowed the potency natural eruption of the impacted tooth. After 24-months of treatment, the impacted maxillary canines took place as integral elements in dentition and Class I Canine relationship was achieved. The success of this comprehensive orthodontic treatment also considered biomechanical and periodontal condition during treatment based on proper evaluation and good prognostic of the impacted tooth position. Providing adequate space and surgical exposure during levelling aligning phase followed by orthodontic traction and gingivectomy, were the multidisciplinary approaches of this following case. In conclusion, biomechanical orthodontic treatment related to periodontal condition must be considered in comprehensive orthodontic treatment of adult patient.

Key words: comprehensive orthodontic treatment, palatal canine impaction, multidisciplinary approach

Abstrak

Perawatan ortodonti komprehensif yang membutuhkan pendekatan multidisiplin pada pasien dewasa berkembang pesat disebabkan pada umumnya mereka tidak berkesempatan memperoleh perawatan ortodonti pada waktu lalu. Kasus impaksi kaninus pada pasien dewasa ini memerlukan integrasi suatu perawatan ortodonti yang menyeluruh. Laporan kasus ini memaparkan perawatan ortodonti seorang pasien perempuan usia 33 tahun dengan profil cembung, impaksi kaninus di palatal dan gigitan silang anterior yang bersifat dental. Pergeseran *midline* yang bersifat dental berkaitan dengan bentuk lengkung rahang yang runcing dan jumlah gigi yang tidak sama pada rahang atas. Penatalaksanaan kasus ini dimulai dengan pencabutan premolar pertama pada sisi yang berlawanan dari regio impaksi untuk mengatasi diskrepansi ruang. Prosedur bedah memungkinkan terjadinya potensi erupsi alamiah dari gigi yang impaksi. Setelah 24 bulan perawatan, posisi kaninus berada dalam lengkung rahang dan tercapai hubungan Kaninus Kelas I. Keberhasilan perawatan ortodonti komprehensif juga mempertimbangkan pilihan biomekanika dan kondisi periodontal berdasarkan diagnosis dan prognosis yang menguntungkan dari posisi kaninus yang impaksi. Penyediaan ruang yang adekuat dan prosedur gingivektomi menjadi salah satu pendekatan multidisiplin dalam kasus ini. Sebagai kesimpulan, bahwa pada perawatan ortodonti komprehensif pasien dewasa perlu dipertimbangkan jenis biomekanika perawatan yang sesuai dengan kondisi periodontalnya.

Kata kunci: perawatan ortodonti komprehensif, impaksi kaninus palatal, pendekatan multidisiplin

INTRODUCTION

The percentage of orthodontics demanded among

adult patients has been increased nowadays since a lot of them could not avail themselves with any treatment decades ago. In addition to aesthetics,

awareness of malfunction problem, recent advances in orthodontic material, and interdisciplinary treatment philosophy have played an important role in making orthodontic treatment popular in adult population. Classification of adult orthodontic procedures includes comprehensive, adjunctive and surgical-orthodontic treatment aspect. There are some indications for adult orthodontic treatment such as: to improve tooth-periodontal tissue relationship, establish an improved plane of occlusion in order to distribute forces through the broadest area, balance the existing space between teeth for better prosthetic replacement, improve occlusion and coordination with the masticatory muscles and the TMJ, satisfy the aesthetic desires of patient. Otherwise, some contraindications in orthodontic treatment are severe skeletal discrepancies, advance local or systemic diseases, excessive alveolar bone loss, inability to obtain a result that the patient or doctor will perceive as satisfactory, poor stability prognosis, lack of patient motivation.^{1,2}

The implication of orthodontic treatment that will take more than six months duration is defined as comprehensive orthodontic treatment. Although the procedural treatment is almost the same in adolescent patients, there are several considerations that must be kept in mind for the adult patients. There are biological limitations in alveolar bone and periodontal tissue that should be considered in adult patients, the lower force level than children, multidisciplinary approaches, esthetic and comfort concerns during orthodontic treatment of adult patients.¹

Teeth normally erupt when half to three quarters of their roots have developed. Teeth with delayed eruption that whose roots are more fully developed but are nevertheless expected to erupt spontaneously. Impacted teeth can be defined as a state when a tooth remains embedded in the oral mucose or bone past its normal eruption period. However, the clinical definition of impacted teeth can be broadened to include teeth that are predicted to undergo an abnormal eruption process or teeth that are causing root resorption of the adjacent teeth, even before the normal eruption period.^{3,4}

The canine is the second most commonly impacted tooth after third molars, with the rate of maxillary impacted canine ranging from approximately 1% to 3%.⁴ The incidence of maxillary canine impaction showed that palatal impaction of maxillary canines occurred 3 to 6 times more often than buccal impaction and more often found in female subjects.^{3,5-6}

The prognosis of treatment should be considered because of treating a malocclusion in which there is an impacted canine will take longer time than si-

milar malocclusion in which all teeth are erupted. Some conditions in related with the prognosis of treatment are the age of the patient, impacted tooth position towards occlusal plane, crown position of impacted canine towards incisive lateral, angulation, and tip of canine cusp in relation to incisive lateral and first premolar.⁷

Management of impacted tooth is begun by determining the location of impacted tooth based on clinical and radiographic examination. Treatment needs to be integrated into the overall orthodontic treatment scheme. First, space must be prepared for tooth in the arch, which generally implies moving adjacent teeth, with or without the extractions. Second, intermaxillary or intramaxillary must be provided for the forces applied to the buried tooth to bring it into alignment. Then, either an open or a closed surgical approach can be used to uncover the crown of an impacted tooth and to place an orthodontic attachment.^{4,7,8}

Due to denser palatal bone, thicker palatal mucose and also more horizontal position, palatally displaced cuspids rarely erupt without requiring complex orthodontic treatment. This case report would describe systematically comprehensive orthodontic treatment of 33-year-old woman with convex profile, palatally impacted of left maxillary canines and single dental crossbite. Dental midline shift associated with narrow arch form of upper arch and asymmetric tooth amount. Management of this case was started by extraction of first upper premolars in the opposite site from impacted maxillary in order to overcome dental discrepancy problem. Surgical exposure allowed the potency natural eruption of the impacted tooth.

CASE

A 33-year-old Chinese female was referred to orthodontic treatment due to tooth impactions and some malocclusions (Figure 1a). Extra-orally, patient appeared to have asymmetrical, leptoprosopic and imbalanced proportion. Her profile was retrognathic (Figure 1b).

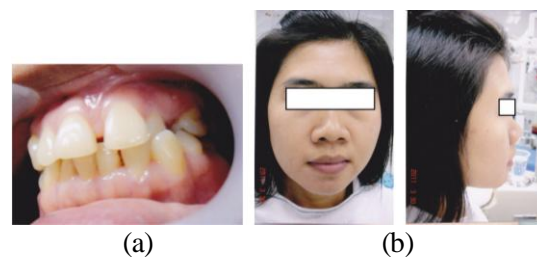


Figure 1. (a) Main complain (b) Extra oral before treatment (Frontal and profile photo)

On intra oral examination, it was found that oral hygiene was quite good. The thick and fibrous frenum in upper arch and gingival recession was found in lower anterior teeth. The palatal depth was moderate (Figure 2). Clinical examination revealed that there was no molar relation due to missing of first molar mandibular. Canine relation was Class II Angle on right side, but the other side had no canine relationship because of impacted of upper left maxillary canine (presence of distinct bulge). The presence of anterior diastema of upper teeth and anterior crossbite that involved teeth elements 22 and 32,42 with the overjet was +4,0 mm (11 with 41); +3,5 mm (21 with 31) and the overbite was +4,0 mm (11 with 41); +3,5 mm (21 with 31). The upper arch was narrow, but the lower arch form was oval. The upper midline dental shifted to the left. Teeth elements of 31 and 41 were rotation (Figure 3).

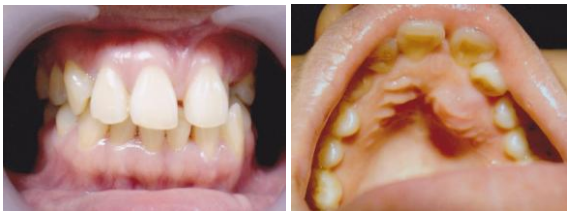

Figure 2. Intra oral photography before treatment

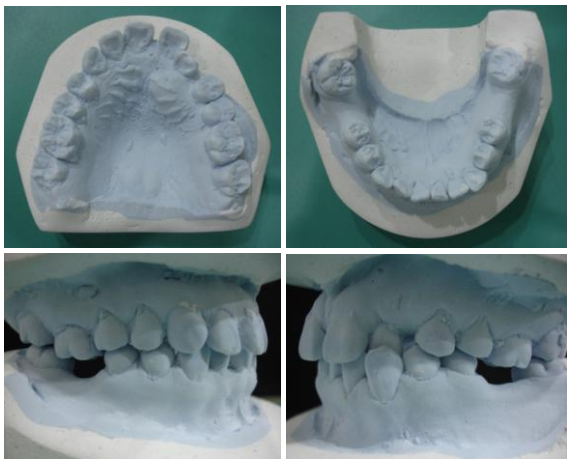

Figure 3. Model study photography before treatment

Functional examination showed that there were no abnormal swallowing and speech. There was no mandibular shifting. The cephalometric analysis in centric occlusion showed normal inclination of upper and lower incisors to skeletal with skeletal class II (protrusive maxilla and normal mandible). Skeletal and soft tissue profile were convex whilst high-angle mandible and mandibular length more than normal value. The proportion of mid and lower face was balance (Figure 4).

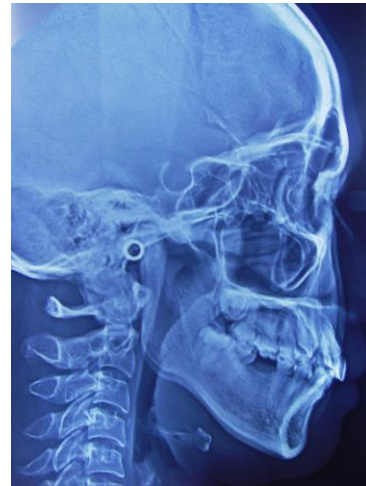

Figure 4. Cephalometric lateral before treatment

The panoramic radiographic examination showed partial eruption of tooth elements 18, 28, 38, and 48 whilst tooth elements 38 and 48 in disto angular position and 18 and 28 in buccoversion. Tooth element of 23 in sector III and the position 11 mm towards occlusal plane. Tip of 23 cusp was more overlapping with the root of 22 than 24. There was extrusion of tooth elements 36 and 46. The maxillary sinus and nasal airways were normal and mandibular ramus were symmetrical (Figure 5a). The position of crown of tooth element 23 was overlapping with the root of 22 (Figure 5b).

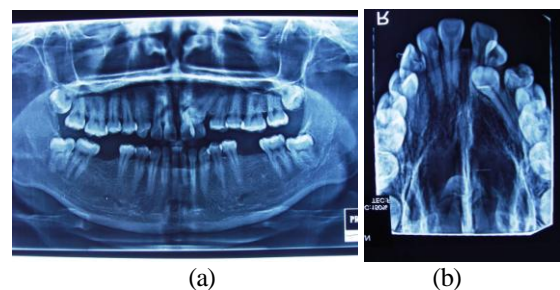


Figure 5. (a) Panoramic before treatment; (b) Occlusal radiography

The aetiologies of this malocclusion related to genetic factor, premature loss of primary teeth, malposition of tooth germ element 23, abnormal eruption sequences, thick and fibrous frenum. Upper arch expansion and extraction of tooth element 14 had been chosen to treat this malocclusion in order to obtain normal overjet and overbite, normal midline, achieved Class I Canine classification. The prostheses were recommended for missing tooth elements 36 and 46 and followed by odontectomy 38 and 48 due to patient rejected procedure mesialisation 37 and 47.

CASE MANAGEMENT

The orthodontic treatment was started with moderate anchorage using molar tube in tooth elements 16, 17, 26 and 27. In the lower arch, molar band of tooth elements 37 and 47 was applied. Then .018 preadjusted (ROTH) bracket appliance was bonded.

Leveling-aligning in upper arch was initiated without involving tooth elements 16 and 26. Leveling aligning in the lower arch was initiated with round archwire. 014 superelastic Ni-Ti. Extraction space of tooth element 14 was done after three months of initial wire. Upper arch midline correction and correction anterior crossbite of Element 22 with crossbite elastics as additional anchorage in round archwire .016 superelastic Ni-Ti. Anterior crossbite correction was obtained in six months after treatment. Releveling aligning procedure of upper arch was continued to obtain midline correction to the right concurrently regaining space for the tooth element 23 with open coil spring and elastic midline. Surgical exposure after space had been created by uncover the canine and let it erupt on its own. Tooth element 23 was almost in good level arch in the twelve months after treatments (Figure 6).

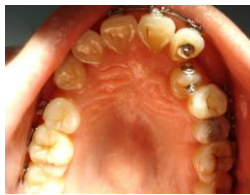

Figure 6. Occlusal view of upper arch twelve months after treatment

In the fourteenth month of treatment, gingivectomy procedure was done and started involving element tooth 23 that was partial erupted. After eighteen months of treatment, palatally impacted maxillary canine was obtained. Releveling and realigning in round archwire superelastic Ni-Ti. Finishing archwire was in rectangular archwire for upper and lower arch. The profile patient was better after treatment eventhough there was slight dental midline shifted to the the right (Figure 7).

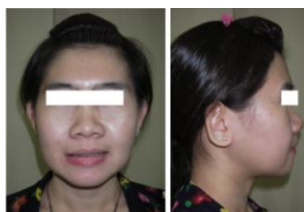

Figure 7. Extra oral after treatment (Frontal and profile photo)

The impacted maxillary canines took place as integral elements in dentition and Class I Canine relationship for both sides was obtained after 24 months of treatment. Both of the overjet and overbite were +3mm. Oval upper arch form and slight midline dental to the right. Partial removable dental was chosen for missing tooth elements 36 and 46 due to obtain good interdigitation (Figure 8). Patient was referred to oral surgeon to get odontectomy procedure of the tooth elements 38 and 48. Root paralleling was achieved and superimposition of cephalometric lateral showed good appearance (Figure 9).

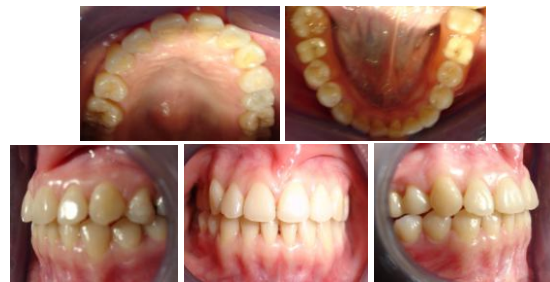

Figure 8. Intra oral photography after 24 months of treatment

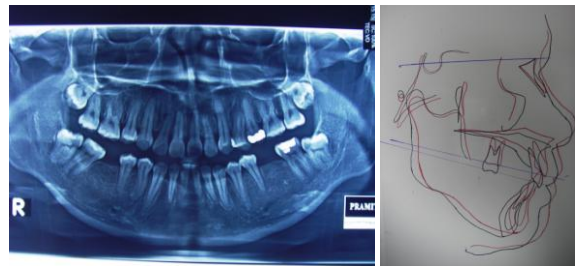


Figure9. (a) Panoramic radiography after 24 months of treatment (b) Superimposition of Cephalometric lateral after 24 months of treatment

DISCUSSION

Since the incidence of impacted maxillary canine was higher in Asians than white people, the case becomes common problem that can be found for most patients who seek and undergo orthodontic treatment. Palatally impacted canines are related to excessive space in the dental arch. The shape of the maxillary arch was narrower and longer in the palatally canine impacted canine group. Deeper palatal vault had also been seen in palatally compared with the buccally impacted canine group. Excessive space in dental is also sometimes being seen. Mesiodistal dimensions of the maxillary teeth including the incisors were reduced significantly. The palatally impacted canine mainly occurred with a normal or belatedly developed dentition, but not frequently

in early developing dentition.³

Through these procedures, canine crown erupts first and “root” instead of the crown moves through bone. When root moves through bone, it lays down bone behind and cause no destruction. On the contrary, if we don’t let tooth erupt but pull inside bone, the enamel of the crown instead of root moves through the bone. When enamel moves through bone, it destroys bone and lays down behind. It can cause the severe periodontal destruction on the adjacent tooth.^{2,6}

The success of this comprehensive orthodontic treatment was influenced by the prognosis of palatally canine impaction position. Force level should be considered because the limitation of responsive periodontal tissue and the age of patient. Although according to Becker et al. who reported about prognosis for successful orthodontic resolution of an impacted canine worsened with age, but was contrary in this case. This condition was suitable with Stewart et al. who reported about the relation of patient’s age at the start of treatment whereas the length of treatment in younger patient was longer. The position of canine impaction towards occlusal plane which less than 14mm (11 mm) had also affected the length of treatment time.^{6,8}

The limitation of comprehensive orthodontic treatment was patient expectation of limited treatment time. Perfect dental with facial midline could not be obtained because of unilateral extraction and loss of anchorage. Function of orthodontic interdigitation and stability of treatment was obtained by class I Canine relationship. The multidisciplinary approaches were also done by gingivectomy procedure during post orthodontic treatment to obtain aesthetic function. The prostheses for missing of lower posterior teeth to obtain the good interdigitation.

In conclusion, the comprehensive orthodontic

treatment for adult patient must consider biomechanical and periodontal condition during treatment based on proper evaluation and good prognosis of the impacted tooth position. Providing adequate space and surgical exposure during levelling aligning phase followed by orthodontic traction and gingivectomy is the multidisciplinary approaches of this following case.

References

1. Bhalajhi SI. eds. Orthodontics: The art and sciences. 4th ed., New Delhi: Arya medi Publishing House Pvt Ltd, 2010: 143-6; 503-10.
2. Karadd A. Current status of orthodontic profession. In: Clinical Orthodontics: Current concepts, Goals, and Mechanics. India: Elsevier, 2010: 305-9.
3. Becker A, Chausu S. Success rate and duration of orthodontic treatment for adult patients with palatally impacted maxillary canines. *Am J Orthod Dentofac Orthop* 2003; 124:509-14.
4. Kim Y, Hyun HK, Jang KT. Interrelationship between the position of impacted maxillary canines and the morphology of the maxilla. *Am J Orthod Dentofac Orthop* 2012; 141:556-62.
5. Meuri E, Cassetta M, Cavallini C, Vicari D, Leonardi R, Barbato E. Skeletal features in patient affected by maxillary canine impaction. *Med Oral Patol Oral Cir Bucal* 2013; 18(4): 597-602.
6. Ajith SD, Shetty S, Hussain H, Nagaraj T, Srinath M. Management of multiple impacted teeth: A case report and review. *J Int Oral Health* 2014; 6(13): 93-8.
7. Kuroi J. Impacted and ankylosed teeth: Why, when, and how to intervene. *Am J Orthod Dentofac Orthop* 2006; 129: S86-90.
8. YH Jung., Liang H., Benson BW, Flint DJ, Cho BH. The assessment of impacted maxillary canine position with panoramic radiography and cone beam CT. *Dentomaxillofacial Radiology* 2012; 41: 356-68.