
MANAGEMENT OF ORAL LESIONS ASSOCIATED WITH CARBAMAZEPINE RELATED STEVENS-JOHNSON SYNDROME / TOXIC EPIDERMAL NECROLYSIS OVERLAP PATIENT

(PENATALAKSANAAN LESI ORAL TERKAIT DENGAN
PASIEN SINDROM STEVENS-JOHNSON DENGAN *CARBAMAZEPINE-RELATED* /
NEKROLISIS RACUN EPIDERMAL YANG TUMPANG TINDIH)

Dewi Puspasari*, Irna Sufiawati**

*Program Pendidikan Dokter Gigi Spesialis Ilmu Penyakit Mulut, Fakultas Kedokteran Gigi,
Universitas Padjajaran, Bandung-Indonesia;

**Departemen Ilmu Penyakit Mulut, Fakultas Kedokteran Gigi
Universitas Padjajaran, Bandung-Indonesia
Jln. Sekeloa Selatan No.1 Bandung. HP: 081396332244
Email: dewilijado@gmail.com

Abstract

Stevens–Johnson syndrome (SJS)/ Toxic Epidermal Necrolysis (TEN) are acute, self-limited, potentially life-threatening mucocutaneous disease. Oral mucosal involvement manifest as extensive erosions and haemorrhagic crusting, which can interfere oral functions causing odynophagia, inability to tolerate solid foods, and increased aspiration risk. A 40-year-old female patient was referred from Dermatology and Venereology department with diagnosis SJS/TEN overlap. The patient complained mouth opening difficulty due to mouth and lip sores. Drug history revealed positive intake of carbamazepine. Extraoral examination revealed multiple diffuse discrete facial lesions, conjunctival hyperemia, erosions and hemorrhagic crusting lips. Intraoral examination revealed white yellowish plaque, and erosions on buccal mucosa, palate, floor of the mouth, dorsal, ventral, and lateral tongue. Laboratory investigation revealed decrease of haemoglobin, hematocrite, Mean Corpuscular Volume (MCV), Mean Corpuscular Hemoglobin (MCH), thrombocyte, eosinophil, band of eosinophil, lymphocyte, natrium, potassium, and calcium. Oral lesions associated with SJS/TEN overlap diagnosis was made. Chlorhexidine gluconate 0,1%, nystatin oral suspension, vitamin B₁₂, folic acid, and corticosteroid unguent compounding were given, which showed improvement of oral lesions in 3 weeks. SJS/TEN are the same disease spectrum of delayed hypersensitivity reaction leading to keratinocyte apoptosis through cytotoxic T-cell mediated Fas-Fas ligand, perforin/ granzyme B, and granulysin, which distinguished primarily by severity and percentage of total body surface area involved. Currently, an optimal treatment standard for SJS/TEN patients remains unavailable. Oral lesions management play significant role in enhancing patients' quality of life and achieving better prognosis in SJS/TEN overlap patients through multidisciplinary approach.

Key words: Oral lesions, Stevens-Johnson syndrome, toxic epidermal necrolysis

Abstrak

Stevens–Johnson syndrome (SJS)/ Toxic Epidermal Necrolysis (TEN) merupakan penyakit mukokutan akut, sembuh sendiri, serta berpotensi membahayakan nyawa. Keterlibatan manifestasi oral berupa erosi ekstensif dan krusta hemoragi yang dapat mengganggu fungsi oral sehingga terjadi odinofagia, sulit mengunyah makanan padat, serta peningkatan risiko aspirasi. Seorang perempuan, 40 tahun dirujuk dari Departemen Ilmu Kulit dan Kelamin dengan diagnosis SJS/TEN *overlap*. Keluhan pasien meliputi kesulitan membuka mulut akibat sariawan pada bibir dan mulut. Riwayat obat menunjukkan konsumsi karbamazepin. Pemeriksaan ekstraoral ditemukan lesi multipel *discrete* difus, konjungtiva hiperemia, erosi dan krusta hemoragi pada bibir. Pemeriksaan intraoral ditemukan erosi pada mukosa oral. Pemeriksaan laboratorium ditemukan penurunan kadar haemoglobin, hematokrit, MCV, MCH, trombosit, eosinofil, eosinofil batang, limfosit, natrium, kalium, serta kalsium. Diagnosis ditegakkan sebagai lesi oral terkait SJS/ TEN *overlap*. Lesi oral mengalami penyembuhan setelah diberikan terapi klorheksidin glukonat 0,1%, suspensi oral nistatin, vitamin B₁₂, asam folat, serta kortikosteroid topikal selama 3 minggu perawatan. SJS/ TEN merupakan spektrum penyakit yang serupa akibat reaksi hipersensitivitas tipe IV sehingga menyebabkan apoptosis keratinosit melalui sel T sitotoksik yang

diperantarai ligan Fas-Fas, perforin/ granzyme B, serta granulysin, yang dibedakan terutama berdasarkan tingkat keparahan dan keterlibatan persentase total epidermolisis permukaan kulit tubuh. Sejauh ini belum terdapat penatalaksanaan standar optimal untuk pasien SJS/ TEN. Penatalaksanaan lesi oral berperan penting dalam meningkatkan kualitas hidup pasien dan dalam upaya memperoleh prognosis lebih baik pada pasien SJS/ TEN melalui multidisiplin ilmu.

Kata kunci: Lesi oral, *Stevens-Johnson syndrome*, *toxic epidermal necrolysis*

INTRODUCTION

An adverse drug reactions (ADR) is defined by the World Health Organization (WHO) as a response to a medicine which is noxious and unintended, and which occurs at doses normally used in man, while drug allergy defined as an immunologically IgE or non-IgE mediated drug hypersensitivity reaction.¹ ADR is a global phenomenon which affects all ages, with implicated risk factors including drug related factors that affect its immunogenicity include its ability to act as a hapten, a prohaptent or to bind covalently to immune receptors (P-i concept).² The host related factors including increasing age and drugs intake, female appear more likely to develop drug allergies than males, concomitant disease states such as immunosuppressed patients and autoimmune disorders may predispose to the development of allergic drug reactions by altering metabolic pathways and inducing variations in the immunologic responses to drugs. The host genetic factor related with human leukocyte antigen (HLA) genotypes. It has been suggested that major histocompatibility complex (MHC) presentation of drug derived antigen plays a key role in the development of drug hypersensitivity.¹

Drug eruptions or ADR range from transient erythema to life-threatening severe cutaneous adverse reactions (SCAR) include drug-induced hypersensitivity syndrome (DiHS), acute generalized exanthematous pustulosis (AGEP), drug reaction with eosinophilia and systemic symptoms complex (DRESS), Stevens-Johnson syndrome (SJS), and toxic epidermal necrolysis (TEN).^{1,2} SJS/ TEN represent different degrees of the same type of SCAR with high morbidity and mortality rates.³ The incidence of SJS specific ranges from 1.2 to 6 per million/ year, with fatality in 5% of cases, while TEN affects 0.4 to 1.2 per million/ year with mortality of 30% of patients.⁴ The incidence of SJS/TEN in South East Asia is largely undetermined.⁵

SJS/TEN are acute, self-limited, rapid onset, rare but severe, potentially life threatening mucocutaneous disease clinically characterized by widespread epidermal necrosis with involvement of at least 2 mucous membranes, which predominantly

triggered by ADR, rarely infections and malignancies.^{4,6} There are over 100 medications of various classes associated with the occurrence of SJS/ TEN.⁴ The high risk implicated drugs include antigout (allopurinol), antiepileptic (carbamazepine/ CBZ, phenytoin, phenobarbital, lamotrigine), antibiotic (cotrimoxazole and other sulphonamides, fluoroquinolone), anti-inflammatory (sulfasalazine), anti-HIV (nevirapine), oxycamderivative nonsteroidal antiinflammatory drugs (meloxicam), and analgesic (paracetamol).^{3,5,7} SJS/ TEN mostly results from a cumulative effect of aligned risks related to drug structure and to the patient's genetic predisposition (HLA alleles, drug metabolism characteristics, and T cell clonotypes),³ as well as ethnic specific.⁵ SJS/ TEN were historically considered part of a spectrum of erythema multiforme major, as they all present with mucosal lesions clinically similar, but these diseases are now considered apart.^{4,8} SJS is defined by 10% or less of total body surface area involvement while TEN is defined by 30% or greater involvement. Body surface involvement between 10–30% is known as SJS/ TEN overlap.⁶

Oral mucosal involvement manifests as extensive erosions and haemorrhagic crusting, which can interfere oral functions causing odynophagia, inability to tolerate solid foods, and increased aspiration risk. The treatment of SJS/ TEN is multidisciplinary approach and there are still no internationally accepted management guidelines or an optimal treatment standard for SJS/ TEN.³ In this case report, we present a case of oral lesions management in SJS/ TEN overlap patient.

CASE REPORT

A 40-year-old female patient was referred from Dermatology and Venereology department with diagnosis SJS/ TEN overlap. The patient reported that she had chronic jaw pain for approximately 3 years since her last dental extraction. Three months before admitted to hospital, she went to her regular dentist who referred her to a neurology specialist. Two we-

eks before admitted to hospital, the neurology specialist prescribed her CBZ. She complained red eye, mouth opening difficulty due to mouth and lip sores, and widespread rashes on her neck, one day before admitted to hospital with preceding fever. She stated that she had no history of allergy.

Extraoral examination revealed multiple diffuse discrete facial lesions, conjunctival hyperemia, eyes and ears secrets, erosions and hemorrhagic crusting lips, and her whole body except scalp, palms, and sole of feet was covered with multiple rashes, vesicle, and epidermolysis bullae. Intraoral examination revealed white yellowish plaque, and erosions on buccal mucosa, palate, floor of the mouth, dorsal, ventral, and lateral tongue (Fig. 1).

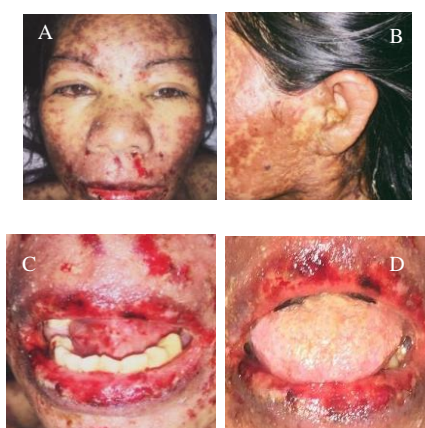

Fig.1A-C. Clinical manifestations of SJS/ TEN overlap showed widespread rashes (A), ear secrets (B), multiple erosions and hemorrhagic crust on lips (C), and oral candidiasis on dorsal tongue (D).

Laboratory investigation revealed decrease of haemoglobin, hematocrite, MCV, MCH, thrombocyte, eosinophil, band of eosinophil, lymphocyte, sodium, potassium, and calcium. Oral lesions associated with SJS/ TEN overlap diagnosis was made.

CASE MANAGEMENT

The patient was hospitalized for 2 weeks and within this periode, regimen from dermatology and venereology department include dexamethasone 30 mg via IV, omeprazole 40 mg via IV, ibuprofen 500 mg three times daily, cendo lyteers 1 ml every one hour. We treated the oral lesions with topical corticosteroid (TC) unguent compounding of corticosteroids (dexamethasone) 0.05 mg + antihistamine (pheniramine maleate: avil) 0.5 mg + emollient base (lanolin) 2.5 g + petroleum jelly based (vaseline) 25 g] three times daily, chlorhexidine gluconate 0,1% three times daily, nystatin oral suspension 2 ml four

times daily, vitamin B₁₂ 50 mcg three times daily, and folic acid 1 mg once daily. All oral lesions gradually resolved in 3 weeks (Fig. 2,3, and 4).

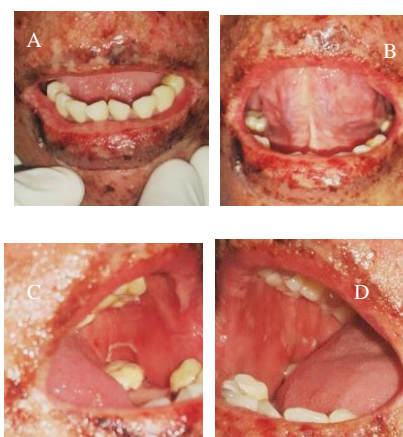


Fig.2A-D. Slight improvement of lesions in first visit or 1-week-follow-up.

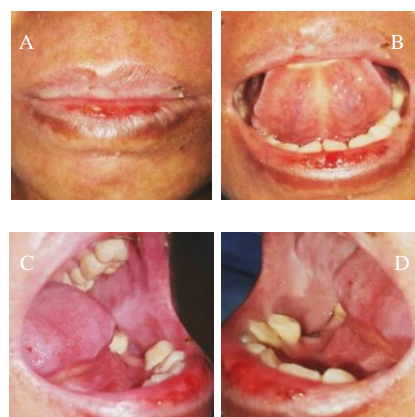


Fig.3A-D. Improvement of lesions in second visit or 2-week-follow-up.

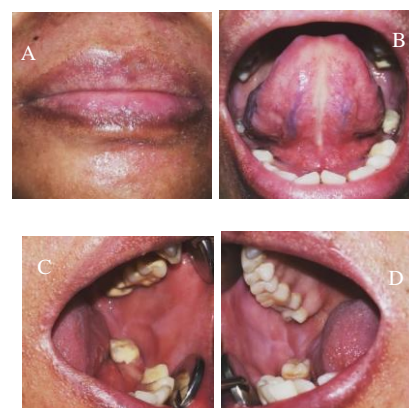

Fig.4A-D. Lesions healed in third visit or 3-week-follow-up.

DISCUSSION

There was history of CBZ intake, two weeks before patient admitted to hospital. SJS/ TEN is an immune disorder mostly caused by drugs, rarely infections (especially *Mycoplasma pneumonia*), human immunodeficiency virus (HIV), vaccinations, radiotherapy and concomitant diseases such as graft versus host disease (GVHD), lymphomas, leukaemias and systemic lupus erythematosus.² CBZ is an antiepileptic drugs (AED) that is effective in some people with chronic neuropathic pain,⁹ but the use of aromatic AED include CBZ, phenytoin, oxcarbazepine, phenobarbital, primidone, zonisamide, and lamotrigine is more frequently associated with drug-induced hypersensitivity reactions such as SJS/ TEN.^{4,5,7,10} The highest risk of developing SJS/ TEN occurs in the first 2 months of treatment with the usage of drugs on a continuous basis.⁴ The risk/ predisposing factors of drug-induced SJS/ TEN include specific HLA allele, pharmacogenetic variations in drug biotransformation or clearance, sex, hormones, drug doses or titration schedule (low dose <10 mg/day and gradual titration may allow desensitization and pharmacodynamics tolerance), and comedication. The chemical structures of aromatic ring in AED might induce allergy via T-cell-mediated (delayed type IV) hypersensitivity reactions.¹⁰

CBZ is one of example of the p-i concept (pharmacological interaction of drugs with immune receptors). The low molecular weight drug act as foreign antigen which binding directly and reversibly to T cell receptors (TCRs), then involved in presenting to HLA molecules of antigen-presenting cells (APCs) and provoke T cell activation. The HLA-drug-TCRs may initiate a series of immune reactions, which result in activation of CD8+ cytotoxic T cell-mediated and natural killer (NK) cell-mediated cytotoxicity. While CD8+ cytotoxic T cells and NK cells are activated, they subsequently carry out the cellular-mediated immune reactions directed at keratinocytes in an HLA class I-restricted manner. Upon activation of these responses, various cytotoxic signaling molecules or cell death mediators, including granzyme, perforin/granzyme B, and Fas/ Fas ligand, and annexin A1 are relayed to the skin lesions to induce keratinocyte apoptosis. Several cytokines/chemokines involved in the pathogenesis of SJS/TEN include interleukin (IL)-2, IL-5, IL-6, IL-10, IL-12, IL-13, IL-15, IL-18, chemokine (C-C motif) receptor (CCR) 3, chemokine (C-X-C motif) receptor (CXCR) 3, CXCR4, and CCR10, which can induce cell apoptosis, activation, and differentiation, and an inflammatory response.^{3,11}

The patient's complaint began with a preceding fever following with red eye, mouth opening difficulty due to mouth and lip sores, and widespread rashes on her neck, one day before admitted to hospital. The onset of signs and symptoms of SJS/ TEN occurs 4 to 28 days after drug exposure, which can start, although not always, with typical or classical prodromal phase that may precede the rash by 1-2 days and lasting up to 1 week, consists of unspecific initial flu-like symptoms (malaise, fever, anorexia), sore throat, coughing, eye burning, myalgia and arthralgia. After this period, The initial skin rash, which appear suddenly and symmetrically, may be erythematous maculopapular with irregular shape or similar to a morbilliform rash, urticarial, purpuric or targetoid and is specifically tender. They usually begins on the presternal region of the trunk and rapidly spread over 3-12 days to involve the face, neck and extremities, also the palms and soles. Macular lesions become purplish or dusky dark red purpuric, with tendency to rapidly develop flaccid blisters that coalesced as atypical target lesions and break, resulting epidermal detachment in erythematous, oozy, raw lesions, and extensive sloughing of necrotic skin, which can easily become infected. The Nikolsky's sign is positive in perilesional skin if mechanical pressure induces epidermal detachment, although it is not specific for SJS/ TEN, as it can also be positive in autoimmune bullous skin diseases. Mucosal involvement may precede or follow the skin manifestations and occurs in two or more distinct mucosal surfaces such as ocular, ear, nose, and throat (ENT), oral, and genital lesions with clinical morphologies include erythema, enanthem, edema, and vesiculobullous that cause painful hemorrhagic erosions, coated by greyish-white pseudomembranes formations.^{3,4,8,11-3} Involvement of oral mucosa is seen in most of the cases with burning sensation, edema and erythema following with widespread and painful mucosal erosions or ulcerations, mostly on buccal, palatal mucosa, tongue, gingiva and lips.^{12,14} The extensive erosions and haemorrhagic crusting can interfere oral functions causing odynophagia, inability to tolerate solid foods, and increased aspiration risk.^{12,15} All the clinical manifestations of SJS/ TEN overlap in our patient is concordant with the literature explained above.

There is still no universal diagnostic criteria for SJS/ TEN.¹⁶ The diagnosis of SJS/ TEN is based on anamnesis, clinical manifestations, and histopathological findings.^{3,4,11} All medications, regardless of the route of administration, must be considered, especially new drugs taken in the 8 weeks prior to the skin reaction. Assessment of the lag period (the time

between initiation of the drug and the onset of the cutaneous reaction) is 4–28 days for SJS/TEN which crucial in view of the different lag times for different cutaneous drug reactions. A comprehensive physical examination consists of prodromal phase, followed by erythema, maculopapular rash, targetoid lesions, bullae, desquamation, mucosal inflammation, and/or positive Nikolsky sign and with other systemic involvement must be assessed to get accurate diagnosis of SJS/TEN. To distinguish SJS, SJS-TEN overlap and TEN, Bastuji-Garin et al. proposed patient classification based on the body surface area percentage of skin detachment (% BSA). SJS is characterized by <10% BSA affected, SJS-TEN Overlap is between 10 and 30% BSA, and TEN is >30% BSA.^{3,4,8,11,16} Based on % BSA finding and having 2 or more mucosal membrane involvement, our patient categorized as SJS/TEN overlap. Laboratory investigation in our patient revealed decrease of haemoglobin, hematocrite, MCV, MCH, thrombocyte, eosinophil, band of eosinophil, lymphocyte, sodium, potassium, and calcium. Various laboratory abnormalities were noted in several SJS/TEN patients such as increased markers of acute inflammation. There are still no specific laboratory investigations.^{3,4,11} Furthermore, there is still inconsistency in the indication for biopsy as an inclusion criterion,¹⁶ with characteristic histopathology reveals keratinocyte necrosis and varying degrees of dermal-epidermal separation.^{3,16} Based on anamnesis, clinical examinations, and without biopsy examination, we diagnosed the case of our patient as oral lesions associated with SJS/TEN overlap.

There are still no internationally accepted management guidelines of SJS/ TEN. Management of SJS/ TEN involves the early identification and removal of the triggers, particularly drugs known to be high-risk, followed by multidisciplinary approach to alleviate symptoms and prevent further complications of the disease. There are several pharmacological therapies available, such as corticosteroids, intravenous immunoglobulins (IVIG), and cyclosporine. However, a universally accepted drug treatment regimen has not been established, and much controversy exists as to the role of each of these drugs individually or in combination.^{3,4,13} The role of corticosteroids in treatment of SJS/ TEN is controversial because it may promote infectious complications and lead to a poorer prognosis. However, corticosteroid treatment did not increased mortality

in SJS/ TEN patients. The patient was hospitalized for 2 weeks and dexamethasone IV, omeprazole IV, ibuprofen, and ceftriaxone were given by dermatology and venereology specialist. Systemic corticosteroids with a high dose are considered to be able to suppress the intensity of immune reaction, control the extension of the necrolytic process, decrease the injury area, reduce fever and discomfort, and prevent damage to internal organs in SJS/ TEN patients at the early stage. Furthermore, a review of the highest quality evidence concluded that steroid use in patients with SJS, SJS/TEN overlap, and TEN does not reveal an increase in mortality.¹³

We treated the oral lesions with TC, chlorhexidine mouthwash, vitamin B₁₂, and folic acid, which resolved in 3 weeks. Mucosal hygienic maintenance are of prime importance to increase patient's comfort, to facilitate epithelialization and to prevent complications such as infections.¹⁷ Specific oral care strategies can be used to minimize trauma during oral functions such as using smaller utensils and syringes.¹⁵ Corticosteroids play a central role in the treatment of vesiculo erosive oral lesions of autoimmune and or immunologically mediated diseases, but the evidence for the efficacy of TC in oral medicine is limited, and many of the protocols followed are drawn from experience gained in a dermatological use.¹⁷ Those major challenges becomes more problematic as there are very few commercial products are currently available for the topical treatment of the oral mucosal lesions. Therefore, compounding is often required.¹⁸ Other drugs of choice to treat erosions include chlorhexidine, octenisept or polyhexanide solutions and impregnated nonadhesive mesh gauze.⁸ Vitamin B₁₂ and folic acid were given in order to induce erythropoiesis. Other pharmacological therapy can be delivered, if needed, such as topical lignocaine gel, antifungal agents (nystatin), others antiseptic mouthwash (e.g., bicarbonated soda, half-strength hydrogen peroxide), and topical cream to the lips (e.g., vasoline, lanolin).^{15,19,20}

Oral lesions management play significant role in enhancing patients' quality of life and achieving better prognosis in SJS/TEN overlap patients through multidisciplinary approach. Comprehensive management of oral lesion in SJS/ TEN overlap including topical corticosteroid, oral hygiene instruction, and patients' adherence.

REFERENCES

1. Thong BYH, Tan TC. Epidemiology and risk factors for drug allergy. *Br J Clin Pharmacol* 2011; 71(5): 684–700.
2. Verma R, Vasudevan B, Pragasaam V. Severe cutaneous adverse drug reactions. *Medical Journal Armed Forces India* 2013; 69: 375–83.
3. Dodiuk-Gad RP, Chung WH, Valeyrie-Allanore L, Shear NH. Stevens–Johnson syndrome and toxic epidermal necrolysis: an update. *Am J Clin Dermatol* 2015; 16(6): 473–93.
4. Wong A, Malvestiti AA, Hafner MFS. Stevens–Johnson syndrome and toxic epidermal necrolysis: a review. *Rev Assoc Med Bras* 2016; 62(5): 468–73.
5. Lee HY, Martanto W, Thirumoorthy T. Epidemiology of Stevens–Johnson syndrome and toxic epidermal necrolysis in Southeast Asia. *Dermatologica Sinica* 2013; 31(4): 217–20.
6. Saeed HN, Chodosh J. Immunologic mediators in Stevens–Johnson syndrome and toxic epidermal necrolysis. *Seminars in Ophthalmology* 2016; 31(1-2): 85–90.
7. Patel TK, Barvaliya MJ, Sharma D, Tripathi C. A systematic review of the drug - induced Stevens–Johnson syndrome and toxic epidermal necrolysis in Indian population. *Indian J Dermatol Venereol Leprol* 2013; 79(3): 389–98.
8. Mockenhaupt M. The current understanding of Stevens–Johnson syndrome & toxic epidermal necrolysis. *Expert Rev Clin Immunol* 2011; 7(6): 803–15.
9. Wiffen PJ, Derry S, Moore RA, Kalso EA. Carbamazepine for chronic neuropathic pain and fibromyalgia in adults. *Cochrane Database of Systematic Reviews* 2014; 4: 1–47.
10. Błaszczyk B, Lason W, Czuczwar SJ. Anti-epileptic drugs and adverse skin reactions: an update. *Pharmacol Rep* 2015; 67(3): 426–34.
11. Harr T, French LE. Toxic epidermal necrolysis and Stevens–Johnson syndrome. *Orphanet Journal of Rare Diseases* 2010; 5(39): 1–11.
12. Bequignon E, Duong TA, Sbidian E, Valeyrie-Allanore L, Ingen-Housz-Oro S, Chatelin V, et al. Stevens–Johnson syndrome and toxic epidermal necrolysis ear, nose, and throat description at acute stage and after remission. *JAMA Dermatol* 2015; 151(3): 302–7.
13. Law EH, Leung M. Corticosteroids in Stevens–Johnson syndrome/toxic epidermal necrolysis: current evidence and implications for future research. *Annals of Pharmacotherapy* 2015; 49(3): 335–42.
14. Sangwan A, Saini HR, Sangwan P, Dahiya P. Stunted root development: A rare dental complication of Stevens–Johnson syndrome. *J Clin Exp Dent* 2016; 8(4): 462–4.
15. Clayton NA, Kennedy PJ. Management of dysphagia in toxic epidermal necrolysis (TEN) and Stevens–Johnson syndrome (SJS). *Dysphagia* 2007; 22: 187–92.
16. Lim VM, et al. A decade of burn unit experience with Stevens–Johnson syndrome/toxic epidermal necrolysis: clinical pathological diagnosis and risk factor awareness. *Burns* 2016; 42(4): 836–43.
17. González-Moles MA, Scully C. Vesiculo-erosive oral mucosal disease-management with topical corticosteroids: (1) fundamental principles and specific agents available. *J Dent Res* 2005; 84(4): 294–301.
18. Sánchez-Regana M, Llambí-Mateos F, Salleras-Redonnet M, Iglesias Sancho M, Collgros Totosaus H, Umbert-Millet P. La formulación magistral en la terapéutica dermatológica actual. *Actas Dermosifiliogr* 2013; 104 (9): 738–56.
19. Reddy RBV, Shekar PC, Chandra KLP, Aravind RS. Oral lesions associated with nevirapine-induced Stevens–Johnson syndrome and toxic epidermal necrolysis: a report of 10 cases. *J Oral Maxillofac Pathol* 2013; 17(3): 431–35.
20. Wetter DA, Camilleri MJ. Clinical, etiologic, and histopathologic features of Stevens–Johnson syndrome during an 8-year period at Mayo clinic. *Mayo Clinic Proc* 2010; 85(2): 131–8.