
ASSESSMENT OF PUSHBACK Z-PLASTY METHOD ON VELOPHARYNGEAL FUNCTION AND ARTICULATION IN POST-RECONSTRUCTION CLEFT PALATE PATIENTS IN HARAPAN KITA CHILDREN AND MATERNITY HOSPITAL JAKARTA

(PENILAIAN METODE *PUSHBACK Z-PLASTY* PADA FUNGSI VELOPHARYNGEAL DAN
ARTIKULASI PASCA REKONSTRUKSI PADA PENDERITA CELAH LANGIT-LANGIT DI
RUMAH SAKIT IBU DAN ANAK, HARAPAN KITA JAKARTA)

Olivia Avriyanti Hanafiah*, Kasman Manullang**, Mantra Firman**, M.SyafrudinHAK***

*Department of Oral Surgery, Faculty of Dentistry, USU

**Department of Oral Surgery, Faculty of Dentistry, UNPAD

*** Harapan Kita Children and Maternity Hospital, Jakarta

E-mail: olivia_avriyanti@yahoo.com

Abstract

Cleft palate patients experience various problems, especially those affecting their speech intelligibility, such as speech articulation disorder. The aim of this research was to prove the effect of cleft palate reconstruction with modified pushback z-plasty technique at the nasal mucosa on velopharyngeal function and articulation function in speaking. A research has been conducted on post-reconstruction cleft palate patients by using modified pushback z-plasty technique at the nasal mucosa. The methods were examining velopharyngeal components with cephalometric radiograph, assessing airflow released from the nose when the patients pronounce vowel 'a' using nasal emission device and assessing speech articulation results through Sehati Program at Harapan Kita Children and Maternity Hospital, Jakarta. The research results showed that there was a statistically significant effect of cleft palate reconstruction with pushback z-plasty technique at the nasal mucosa on velopharyngeal function, and there was a statistically significant effect of cleft palate reconstruction with pushback z-plasty technique at the nasal mucosa on articulation function in speaking. In addition, there was also a statistically significant correlation between velopharyngeal function and speech articulation function of post-reconstruction cleft palate patients with pushback z-plasty technique at the nasal mucosa based on the cephalometric radiograph, but the result was not significant statistically based on nasal emission assessment.

Key Words: cleft palate patients, modified pushback z-plasty technique at the nasal mucosa

Abstrak

Penderita celah langit-langit mengalami berbagai masalah khususnya yang mempengaruhi kejelasan berbicara di antaranya adalah gangguan artikulasi bicara. Tujuan dari penelitian ini adalah untuk membuktikan pengaruh rekonstruksi celah langit-langit dengan teknik modifikasi *pushback z-plasty* pada mukosa nasal terhadap fungsi velofaring dan fungsi artikulasi bicara. Telah dilakukan penelitian terhadap penderita pascarekonstruksi celah langit-langit dengan teknik modifikasi *pushback z-plasty* pada mukosa nasal dengan melakukan penilaian komponen velofaringeal menggunakan cefalometri radiografi dan penilaian udara yang lolos dari hidung menggunakan alat ukur nasal emisi, saat mengucapkan huruf vokal 'a' serta penilaian hasil artikulasi bicara di Program Sehati RSAB Harapan Kita Jakarta. Hasil penelitian adalah adanya pengaruh yang bermakna secara statistik dari rekonstruksi celah langit-langit dengan teknik *push back z-plasty* pada mukosa nasal terhadap fungsi velofaringeal dan adanya pengaruh yang bermakna secara statistik dari rekonstruksi celah langit-langit dengan teknik *push back z-plasty* pada mukosa nasal terhadap fungsi artikulasi bicara serta terdapat korelasi antara fungsi velofaringeal dengan fungsi artikulasi bicara pada penderita pasca rekonstruksi celah langit-langit dengan teknik *pushback z-plasty* pada mukosa nasalyang bermakna secara statistik dari penilaian cefalometri dan tidak bermakna secara statistik dari penilaian nasal emisi.

Kata Kunci: penderita celah langit-langit, teknik modifikasi *pushback z-plasty* pada mukosa nasal

INTRODUCTION

Cleft palate is a congenital abnormality or defect which is varied in the width of the gap and can be either with or without cleft lip, complete or incomplete, and bilateral or unilateral. This congenital defect can lead to dysfunction in speaking, swallowing, blowing, and chewing ability. Furthermore, it can also result in a disturbance in the growth and development of jaw, eruption, and dental occlusion, as well as the ear, nose, and throat. Cleft palate patients' experience various problems affecting their speech intelligibility. In this case, one of the causes is dysfunction in speech articulation. The functions of articulation mechanisms are to solve and modify laryngeal tone and form a new sound in the mouth cavity. The most important new sound is consonants. However, cleft palate patients have difficulties in pronouncing linguo dento palatal consonants / t / and / d and linguo palatal consonants / k / and / g. The failure to pronounce these consonants is followed by the failure to pronounce words and sentences, even the whole speech process.¹

Physiologically, lips and palate have an important role in the formation of speaking voice. Speech disorders for cleft palate patients are including hyper nasal resonance, nasal emission, weak pressure consonants, and compensatory articulation gestures.²

In order to diagnose speech disorders of cleft palate patients, an evaluation is conducted by doing perceptual assessment and instrument assessment. The perceptual assessments are including past history, mouth cavity structure, resonance, nasal emission, and articulation whereas the instruments which can be used as diagnostic examination are cephalometry, nasometer, video fluoroscopy, nasopharyngoscopy, pressure flow technique, and electromyography.²

To overcome speaking difficulties of the cleft lip and palate patients, the gap closure should be performed with labioplasty and palatoplasty surgery. However, the surgery does not guarantee that the patients can speak perfectly because it depends on various factors, such as types of the cleft, surgical techniques, age during the surgery, and number of visits to speech therapy after the cleft palate reconstruction.³

Furthermore, vowel letters are needed to pronounce consonants. One of the vowels is 'a'. Cephalometric examination by pronouncing the vowel 'a' is the simplest and easiest method which can be done for children under five years old.⁴ Besides that, in order to know the exact velopharyngeal function, it can be done by using consonant letters such as p, b, t, d, k, g.⁵ Nevertheless, the vowel 'a' is expected to evaluate

and determine the extent of the elevation of the soft palate to the posterior pharyngeal wall.

There are several surgical techniques that can be selected to anticipate the occurrence of velopharyngeal insufficiency in the cleft palate patients. One of the surgical techniques for cleft palate popularized by Grabb et al. (1991) is known as a z-plasty modification on pushback palatoplasty technique.

Lip palate patients experience an inability to resist air produced, so the quality of their voice is imperfect.⁶ Meanwhile, cleft palate patients experience an excessive air production through nasal cavity when producing sound due to the inability to close the nasopharynx optimally.

One of the solutions to tackle these problems is by performing a surgery to close the cleft palate. Closing the cleft palate with palatoplasty is aimed to achieve almost normal anatomical form and palate function; thus, it can improve the function of the palate as an articulation organ.

The cleft palate reconstruction technique with pushback technique attempts to move the left and right sides of the mucoperiosteal flap to the back as far as possible (maximum pushback). Moreover, it is combined with z-plasty at the nasal mucosa which is expected to produce a long posterior palate which has a function to close adequate velopharyngeal.⁷

Sehati Program at Harapan Kita Children and Maternity Hospital has performed an integrated treatment for the cleft lip and cleft palate patients. However, the reconstruction of cleft palate has been done by using the pushback z-plasty modification techniques at the nasal mucosa since 1995.

The purpose of this research was to prove the effect of z-plasty in the pushback technique on velopharyngeal function and speech articulation function for the management of cleft palate patients which was specifically aimed to obtain a good velopharyngeal and speech function.

MATERIALS AND METHOD

The research was performed in Sehati Program, The Cleft Lip and Cleft Palate Team at Harapan Kita Children and Maternity Hospital, Jakarta. The research was conducted from July to September 2004. The type of this research was pre-experimental designs classified into one group post-test design by evaluating the assessment results of the cephalometric radiograph, nasal emission, and speech articulation data. The research subjects were patients who fulfilled the inclusion criteria including post-reconstruction cleft palate patients with pushback z-

plasty technique at the nasal mucosa, aged 3-6 years old, and no oronasal fistula after reconstruction of the cleft palate, and physically fit. The population who met the criteria was collected with purposive sampling. Thus, the number of samples (n) who fulfilled the inclusion criteria was 30 subjects. The tools and materials needed for data collection are including cephalometric radiograph, nasal emission device, speech articulation check sheet, informed consent (consent form to participate in the research), books, and stationeries.

After that, the data were collected from the cleft palate patients who had undergone cleft palate reconstruction with pushback z-plasty technique at the nasal mucosa in Sehati Program at Harapan Kita Children and Maternity Hospital, Jakarta. Patients who met the criteria were examined with a cephalometric radiograph, nasal emission device, and speech articulation assessment by using speech articulation check sheet performed by a speech therapist.

Measurement Techniques: (a). A cephalometric radiograph was performed on each sample when pronouncing the vowel 'a'. (b). Nasal emission assessment was performed on each sample using a nasal emission device which was a scale measurement. (c). Secondary data collection was the speech articulation sheet from the examination results of the speech therapist regarding the number of correct words spoken by the patient on the first letter, middle letter, and last letter during the speech therapy practice.

RESULTS

A research has been conducted on 30 patients who had undergone cleft palate reconstruction with pushback z-plasty technique. The aim was to obtain analysis results of cephalometry radiograph and nasal emission when pronouncing the vowel 'a'.

According to the examination results, 23 patients showed elongated soft palate towards superior, and posterior had contact with the posterior pharyngeal wall at 3 points. On the other hand, 2 patients showed elongated soft palate towards superior, and the posterior had contact with the posterior pharyngeal wall at one point whereas 5 patients showed elongated soft palate towards superior, and the posterior did not have contact with the posterior pharyngeal wall.

The results of nasal emission assessment showed that 22 patients did not expose air from the nose when pronouncing the vowel 'a' whereas 8 patients exhaled air about 1-2 cm from the nose when pronouncing the vowel 'a' (Figure 1).

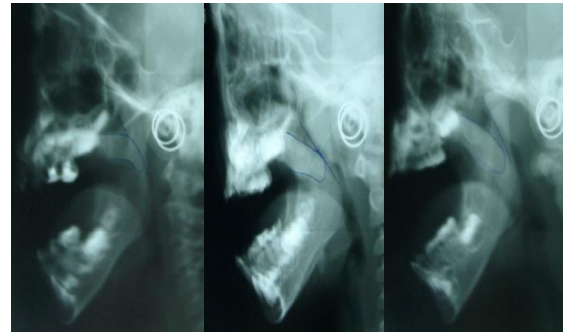


Figure 1. The results of cephalometric radiograph examination when pronouncing the vowel 'a': (1) had contact at 3 points; (2) had contact at 1 point; (3) had no contact

After the data were analyzed statistically with proportion test, the results showed 0.77 on cephalometry and 0.73 on nasal emission. If the expected proportion test result obtained was 80% as the proportion of success, it indicates a non-significant test. It means that statistically the proportion of success can be achieved. In other words, if the result obtained is similar with the expected result from the proportion of 0.8, it indicates that the success which can be seen from the proportion is achieved.⁸

Among 30 patients as the research participants, 14 patients had completed speech therapy practice and obtained excellent speech results. However, 10 patients did not regularly attend the speech therapy practice, and 6 patients never attended the speech therapy practice.

After the data were analyzed with t-test, the results showed that the average correctness of pronunciation on the initial letter, middle letter, and last letter was significant, as follows: the initial letter was 19 with the proportion of 20, the middle letter was 20 with the proportion of 21, and the last letter was 14.93 with the proportion of 16. It indicates that the analysis of the articulation assessment obtained on the initial letter, middle letter, and last letter has not reached the expectation.

After obtaining the secondary data assessment result of speech articulation sheet, and then the data were correlated with the cephalometric radiograph and nasal emission data. The data results were tested with Spearman rank correlation test. The correlation of the cephalometry result and the speech articulation result was found to be statistically significant indicating that there was a connection between cephalometry and speech articulation in the pronunciation of the initial letter, middle letter, and last letter.

It was also found that the correlation of nasal emission result and the speech articulation result was not

statistically significant. This result indicates that there was no connection between nasal emission and speech articulation, either on the pronunciation of the initial letter, middle letter, and last letter.

DISCUSSION

In this research, supporting devices were used, namely cephalometric radiograph and nasal emission when the patients pronounced the vowel 'a'. In addition, the length, and the movement of the soft palate as one component of the velopharyngeal were also assessed. The velopharyngeal function in the mid-sagittal sector clinically includes a two-dimensional movement; however, the closure of the velopharyngeal comprises a three-dimensional movement of the lateral wall, posterior pharynx, and soft palate in the mid-sagittal plane (anteroposterior) and in the coronal plane (lateral). The results of this study proved that the combination of the pushback palatoplasty technique and z-plasty (single opposing z-plasty) technique obtained almost normal velopharyngeal components for a good speech function.

The evaluation of the velopharyngeal function should be done in three dimensions.⁴ According to Berkowitz (1977), lateral cephalogram is the best diagnostic tool for examining patients' ability for velopharyngeal closure in the anteroposterior dimension. Lateral cephalogram data obtained in this study was by analyzing velopharyngeal function with the vowel 'a'.⁴

The vowel 'a' was chosen because it is easy to pronounce especially for children under five years old. In order to know the function of the velopharyngeal properly, consonants such as p, b, t, d, k, g should be used while the vowel 'a' is used to help the consonant letters in evaluating the length of the soft palate elevation to the posterior pharyngeal wall.^{4,5}

The lateral cephalogram may provide information about the length of the soft palate when it is functioning and resting, skeletal variations to determine the form lines of the nasopharynx, the relationship between adenoid tissues and the nasopharynx, and the ability to function of the pharyngeal muscles of neuromuscular.⁹

As the subjects in this research were children under five years old, it was difficult to use fiber optic nasendoscopy because it required a high cooperative level of the patients.

The recruited subjects were post-reconstruction cleft palate patients aged 3-6 years old. Most of the patients felt uncomfortable when being in the radiographing room and when taking pictures because the patients were required to pronounce the vowel 'a' for

approximately 30 seconds until the exposure time of the cephalometric x-ray device was achieved.

However, some patients stopped pronouncing the vowel 'a' before their exposure time was achieved whereas the voice of some patients when pronounced the vowel 'a' kept being softer. The assessment of each patient could only be repeated once if the first result was not good, especially when the child was not cooperative. The purpose was to minimize the effects of radiation on the patients.

The evaluation of the velopharyngeal function could also be done with nasal emission assessment which is measuring the air coming out of the nose when the patient pronounces the vowel 'a'. The patient's speech ability depends on the gap size when the soft palate closes, the articulation ability and the oral motor of the patients.¹⁰

The diagnostic method performed on patients with velopharyngeal insufficiency, particularly in order to see the amount of air which escapes from the nose, is a glass test. The procedures of the glass test are putting the glass under the nose and the patient will be asked to speak. If the glass fogs up, it indicates that there is air coming out of the nose when the patient speaks. Moreover, there are also oral motor assessment and nasal airflow measurement.¹⁰

The results of the nasal emission assessment revealed that most patients who had been reconstructed and attended speech therapy practice regularly in about 2 years showed no air escaping from the nose when they pronounced the vowel 'a'. In contrast, 8 patients still experienced nasal air emission from the nose because they were still in the process of speech therapy or visit the speech therapy practice irregularly.

The results of this research obtained with cephalometric radiograph and nasal emission showed that pushback z-plasty method at the nasal mucosa which was performed on the cleft palate reconstruction and followed with regular speech therapy provided excellent results. In addition, according to the statistical calculation of the proportion of success which was about 80% indicated a non-significant testing property. It implies that the proportion of success can be achieved statistically.

The assessment of the articulation ability in this research was conducted by collecting data from the speech articulation sheet in the last speech therapy practice. According to the data found, 14 patients had completed the speech therapy practice and showed good communication skills because their speech was quite smooth and clear. In addition, their articulation ability was sufficient on all consonants and vowels. However, occasionally the consonant 'R' could not

be pronounced precisely, especially for children aged 4-5 years old.

Of the 10 patients who did not regularly attend the speech therapy practice, five of them showed good articulation ability. This could happen because of the persistence of the patient's parents and surrounding environment including teachers, friends, and other family members to train the patient at home to communicate well. In contrast, the other five patients still had a bad articulation, especially in the pronunciation of r, s, t, d, k, n, g, ng on the pronunciation of the initial letter and the last letter. The other six patients who never attended the speech therapy practice still had a nasal emission on the vocal pronunciation and experienced distortion and substitution when pronounced consonants. Generally, the articulation ability of these patients was not satisfactory. However, there was one patient who was bad at the pronunciation of the letter r, but in general, the articulation ability was quite good. This might be because this patient has entered school and supported by the persistence of his parents and other family members who trained him to communicate well.

Speech therapy is a science that studies and manages problems of language, speech, sound, and smooth rhythm. Sound and speech (articulation) are the problems that often occur in the cleft lip and cleft palate cases. The sound problem includes the quality of the hypernasal sounds due to air leaking into the mouth cavity whereas the speech (articulation) problems include the failure of the articulation point placement, time, air pressure from the lungs, and the speed in the integration of lip, tongue, soft palate, or pharynx movements.¹¹

Speech therapy can improve velopharyngeal function in the case of a minimal velopharyngeal dysfunction, errors in articulation, or post-operation patients. The purposes of the speech therapy practice for the post-reconstruction cleft palate patients are to remove/reduce nasal (hyper nasal) and to improve the articulation disorder. Thus, the patients will be able to communicate well verbally. However, the speech therapy cannot replace the surgical procedures, especially for the patients with specific anatomic deficiencies which preclude adequate velopharyngeal closure.

A regular and continuous speech/language speech practice which focuses on improving the overall oral motor ability as well as increasing the strength and the elevation of the soft palate can improve the velopharyngeal dysfunction.^{10,11}

The speech therapy in Sehati Program at Harapan Kita Children and Maternity Hospital is conducted one month after the palatoplasty through integrated

stages of the speech practice, namely an evaluation of the speech therapy practice. The therapy is conducted after the patient receives the cleft palate reconstruction until good results are achieved or when pharyngeal surgery is indicated for the patients at the age of 18 years old involving the role of parents and other family members.

An explanation of the development possibilities for the voice and speech of the child is also provided for the patient's parents. When the patient comes, the first stage performed by the speech therapist is examining the patient which includes the soft palate movement and the velopharyngeal closure function using a scale stainless steel mirror. The practice will be given every week in the first three months of evaluation. The first stage of the practice is performed on the soft palate to maximize the function of velopharyngeal closure by maximizing the function of the muscles in the soft palate. Also, there is nasality exercise which aims to maximize the closure of the velopharyngeal component and to reduce air released from the nose and the hyper nasality of the patient. Furthermore, as the age of the patients is still young, sometimes it is difficult to have a contact with the patient. Therefore, the parents should also train the patient actively at home according to how the patient is taught by the speech therapist.

After the first stage of practice, the patient is rested for 3 months, so that the patient can practice together with the parents and other family members at home. For example, they can practice communicating with the correct words and sentences, or repeat the exercises as taught by the speech therapist.

Stopping the exercise for a while is also considered as a step to avoid boredom because the patient's age during the speech therapy practice is about 2-3 years old. After the break ends, the speech therapist performs a second evaluation on the patient to see and assess the movement of the soft palate, the velopharyngeal function with stainless steel mirror, and the nasality assessed from the hearing impression. If the result is good, an observation is conducted every 3 months while the patient practices at home until the age of 4 years old. In contrast, if the second evaluation shows an unsatisfactory result, the practice for the soft palate and the nasality is continued for every 3 months until the age of 4 years old. The reason is that a child in the age of 4 years old is cooperative enough to communicate and talk well. However, if the age of the patient has been 4 years old and regularly attends the speech therapy, but the result is still not good, the speech therapist performs a "re-push back operation". After one month of the "re-push back operation", the patient will receive the speech thera-

py practice starting from the first evaluation again. Finally, if the result is still not good, a speech aid is developed, and a third reconstruction is prepared for the patient with an appropriate technique to the indication at the age of 18 years old.¹¹

Approximately 90% of the patients managed by Sehati Program at Harapan Kita Children and Maternity Hospital showed satisfactory speech results, and only about 10% had unsatisfactory speech results. The unsatisfactory speech results might happen because the patients or the patients' parents were uncooperative in attending the speech therapy practice.

The research results also showed that there was a positive effect of attending speech therapy regularly for the post-reconstruction cleft palate patients.

In this research, it has been proven that there was a significant correlation between cephalometry and articulation. It indicates that there was a statistically significant relationship between cephalometry and articulation in the pronunciation of the initial letter, middle letter, and last letter.

In contrast, a non-significant correlation was found between nasal emission and articulation. It indicates that there was no significant relationship between nasal emission and articulation, either on the pronunciation of the initial letter, middle letter, and last letter. In addition, there was a correlation found between velopharyngeal function and speech articulation function, although the statistical analysis showed a non-significant result on the nasal emission. This result indicates that there was a correlation, but it was not statistically significant.

This study also showed that there was a difference in the structure of the muscles between normal people and cleft palate patients. The muscles' structure of normal people converges in the midline with a transversal orientation whereas the muscles of cleft

palate patients are inserted into the posterior edge in the palatine bone with longitudinal bundle orientation direction. This condition causes the muscles might not function optimally and might interfere with its growth and development. The most important muscle disorientations are tensor veli palatini muscle, levator veli palatini, and salpingofaryeus.^{7,12}

Cleft palate patients will form a balance of the velopharyngeal, nasal and tongue mechanisms to produce an intelligible and clear sound. The cleft palate patients will also form a balance of tongue shape and tongue position when speaking to help the air valve coming from the larynx to the pharynx. Similarly, superficial muscles around the nose involved in facial expressions are included to limit the amount of air escaping from the nasal cavity. The posterior and lateral pharyngeal walls produce a strong movement and try to restrict the path between oropharynx and nasopharynx when speaking. The bulge of the pharyngeal wall muscles is formed when there is an attempt to block the path between the oropharynx and the nasopharynx when the cleft palate patient speaks. This bulge is known as Passavant's ridge.⁵ This velopharyngeal closure pattern is useful when the velopharyngeal dysfunction will be corrected by surgical intervention.

In conclusion, the results showed a statistically significant effect of the cleft palate reconstruction with the pushback z-plasty technique at the nasal mucosa on the velopharyngeal function and the speech articulation function. In addition, there was a statistically significant correlation found between velopharyngeal function and speech articulation function in the post-reconstruction cleft palate patients based on the cephalometric radiograph, but the correlation was not statistically significant based on the nasal emission assessment.

REFERENCES

1. Kosowski T, Weathers W, Wolfswinkel E, Ridgway E. Cleft palate. *SeminPlastSurg* 2012; 26: 164-9.
2. Pet M, Grames L, Stahl M, Saltzman B, Molter D, Woo A, The furrow palatoplasty for veropharyngeal dysfunction: velopharyngeal changes, speech improvements, and where they intersect. *The cleft palate-Craniofacial Journal* 2015; 52(1): 12-22
3. Early speech development in children with a cleft palate <<https://www.seattlechildrens.org/pdf/PE1706.pdf>> (22 Juli 18).
4. Cholid Z. Celahpalatum (palatoscizis). *J.K.G Unej* 2013; 10(2): 99-104.
5. Smith B, Kuehn D. Speech evaluation of veropharyngeal dysfunction. *The Journal of Craniofacial Surgery* 2007; 18: 251-6.
6. Goodbole S, Phakan J, Kale S, Prosthodontic consideration of speech in complete denture. *JDMS* 2016; 15(11): 41-4.
7. Yamanishi T, Nishio J, Sako M, Kohara H, Hirano Y, Yamanishi Y, et al. Early two -stages double opposing z-plasty or ones-stage push-back palate-plasty. *Annals of Plastic Surgery* 2011; 66(2): 148-153.
8. Tjokronegoro dan Sudarsono. *Metodologi kedokteran bidang kedokteran*. Jakarta : Balai Penerbit FK UI, 1999: 87-94.
9. Yastani D, Purbiiati M, Astuti I, Krisnawati. Dentocraniofacial morphology in unilateral and bilateral cleft lip and palate following labioplasty and palatoplasty; analysis at first and second cervical vertebral maturation stage.

10. Biavati et al. Velopharyngeal insufficiency. <<http://www.emedicine.com/ent/topic596.htm>>. (4 Juli 2017).
11. Rachimhadi T. Buku pedoman standar tata cara administrasi-keuangan dan medik program sehat. Jakarta: RSAB Harapan Kita, 1996: 1-89.
12. Kriens O. Anatomy of Cleft Palate. In: Bardach JB, Morris HL. Multidisciplinary management of cleft lip and palate. Philadelphia: WB Saunders Company, 1990: 287-302.