
2D PANORAMIC RADIOGRAPHY AND 3D CBCT OF MANDIBULAR CORTICAL LOSS IN SYSTEMIC LUPUS ERYTHEMATOSUS (SLE) PATIENTS OF HASAN SADIKIN HOSPITAL: A CROSS SECTIONAL STUDY

(RADIOGRAFI PANORAMIK 2D DAN CBCT 3D DARI HILANGNYA TULANG KORTIKAL
MANDIBULAR DI SYSTEMIC LUPUS ERYTHEMATOSUS (SLE) PADA PASIEN DI RUMAH
SAKIT HASAN SADIKIN: STUDI CROSS SECTIONAL

Trelia Boel*, Wilda H. Lubis*, Ervina Sofyanti*, Dewi Kartika*, and Wachjudi R. Gunadi**

*Faculty of Dentistry, Universitas Sumatera Utara
Jl. Alumni No.2 Kampus USU Medan 20155
Department of Internal Medicine

**Medical Faculty, Universitas Padjajaran
Jl. Professor Eyckman No. 38, Bandung, 40161
Corresponding email: trelia.boel@usu.ac.id

Abstract

Systemic Lupus Erythematosus (SLE) is an autoimmune rheumatic disease that involves extensive inflammation of the bone regions. Studies showed that the long-term medication in SLE patients affects the quantity and quality of bones. This should be considered in any treatment administered, including dental treatment. This study was conducted to analyze mandibular cortical bone loss in SLE patients with 2D panoramic radiography and 3D Cone Beam Computerized Tomography (CBCT). The research was a cross-sectional study to measure 31 SLE Indonesian female outpatients in Internal Medicine Installation at Hasan Sadikin Hospital, Bandung in 2014. The mean age is 37.65 ± 10.79 years with 5.23 ± 4.37 mg corticosteroid intake history for 2–20 years. There was a significant correlation in the mandibular cortical loss analyzed by 3D CBCT imaging based on corticosteroid dosage ($p=0.026$). In conclusion, the level of mandibular cortical bone loss observed by panoramic radiography was moderate while 3D CBCT imaging showed a severe level of loss in this study.

Keywords: Systemic Lupus Erythematosus, Panoramic Radiography, Cone-Beam Computed Tomography

Abstrak

Systemic lupus erythematosus (SLE) adalah penyakit rematik autoimun yang melibatkan perluasan inflamasi pada region tulang. Berbagai penelitian menunjukkan bahwa penggunaan obat jangka panjang pada pasien SLE mempengaruhi kuantitas dan kualitas tulang. Hal ini harus dipertimbangkan dalam perawatan apa pun yang diberikan, termasuk dalam perawatan gigi. Penelitian ini dilakukan untuk menganalisis kehilangan tulang kortikal mandibular pada pasien SLE dengan radiografi panoramic 2D dan 3D *Cone Beam Computerized Tomography* (CBCT). Jenis penelitian ini adalah penelitian *cross-sectional* pada 31 wanita SLE yang datang berobat ke instalasi Penyakit Dalam Rumah Sakit Hasan Sadikin pada tahun 2014 dengan usia rata-rata $37,65 \pm 10,79$ tahun yang memiliki asupan riwayat kortikosteroid $5,23 \pm 4,37$ mg selama 2-20 tahun. Terdapat hubungan yang signifikan pada kehilangan kortikal mandibula yang dianalisis dengan 3D CBCT berdasarkan dosis kortikosteroid ($p=0,026$). Kesimpulannya, terlihat kehilangan tulang kortikal mandibula level sedang berdasarkan radiografi panoramik, namun level parah berdasarkan gambaran 3D CBCT.

Kata kunci: Systemic Lupus Erythematosus, Radiografi Panoramik, Cone-Beam Computed Tomograph

INTRODUCTION

Systemic lupus erythematosus (SLE) is a severe autoimmune multisystem disease where all antibodies related to the rheumatoid disease is produced

in the body. Pathophysiology process of the disease involves genetics, immunology, hormonal and environment factors. The associations among SLE onset

and age, sex, geography, and race have also been established. Management of this disease should be personalized and included both pharmacological and nonpharmacological modalities for symptom relief and resolution as well as improved quality of life.¹⁻² The rate of SLE in the US is 5.1: 100,000 with 10:1 ratio of sexes between female and male. In Indonesia, SLE cases increase. In 2010, there were 10.5% (n=291) SLE patients who came to Hasan Sadikin Hospital, Bandung to be treated. The survival rate is 85% for the first 10 years and 65% after 20 years of SLE³. A lot of studies have reported severe bone loss related to some systemic diseases. However, there were limited only for SLE patients due to various pathophysiology processes. Some studies indicated that there were significant differences in cortical mandibular bone loss that was limited to the development of this disease severity.⁴⁻⁶

Similar to every other bone in the human body, maxillary and mandibular bones are affected by systemic disease or medical treatment, also local bone diseases that cause the loss of the tooth. Some systemic disorders will lead to extensive inflammation in bone regions including the mandibular cortex. In a healthy woman, every addition of menopause year duration causes the decrease of mandibular cortex thickness by 0.1 mm. Studies reported that the thickness of the mandibular cortex angle reduces in females with osteoporosis when in comparison with a healthy subject.^{1,7-8} Premenopause SLE female patients suffer from significant trabecular and cortical bone losses which increase the risk of fractures in the future. When T score for lumbar spine decreases, mandibular cortex thickness declines significantly and influence tooth loss with bone resorption and osteoporosis in older populations.⁹ In multivariate body mineral density analysis of all parts predicted by age and body mass, there was a reduction in bone mineral density based on the dosage of corticosteroid consumed by perimenopause SLE patients.¹⁰

Recently, Dual-energy X-ray Absorptiometry (DXA) is widely accepted as the gold standard for clinical bone mineral measurement for the spines and femur proximal. DXA is a conventional technique for bone mineral density test with its high precision and accuracy.^{6,11} Although it is the "gold standard" method for a clinical bone mineral test, DXA is yet applied for the measurement of bone mineral density in the jaws.

The change of bone structures in osteoporosis varied with age and the different conditions. While all bone damages occur in skeletal, they may be altered. Besides that, the total loss of peripheral skeletal (a majority of cortical bones) is different from the loss of axial skeletal which mainly includes spongiosa

bone.^{6,11} There are needs to determine the quality of mandibular cortical loss with Mandibular Cortical Index (MCI) panoramic radiography by Klemetti (which can be used in any populations) for normal and populations with osteoporosis. Although it is usually used in dental care, the panoramic radiography interpretation can help in detecting the risk of bone damages related to osteoporosis and long-term consumption of corticosteroid.¹² There is a significant difference in the statistics based on gender, tooth status, width value of cortical mandibular, MCI and panoramic mandibular index in elderly patients (age 66 – 88 years old) with and without osteoporosis.¹³

SLE is a chronic autoimmune multisystem disease with a broad manifestation spectrum from mild skin defect to severe organ damages which are influenced by the different geographic background. The most reported systemic conditions are related to osteoporosis.¹⁴⁻¹⁵ Based on the research done to the population in Asia, prevalence occurs in 30 – 50 people per 100,000 populations. The incidence varied between each country, which is 0.9 – 3.1 / 100,000 and showed similar manifestation.¹⁵ Osteoporosis which is marked with the mass reduction of mandibular bone mass. It has a positive correlation with the loss of nutrition in 269 female patients without metabolic disease or local lesion that affect mandibular cortex based on the study of panoramic radiography.¹⁶ Therefore this study aims to analyze the loss of cortical bones related to osteopenia in SLE patients based on 2D panoramic radiography and 3D Cone-Beam Computed Tomography (CBCT) measurement. Prevalence, severity, and manifestation show a significant variation in all over the world. The objectives of this study are to analyze mandibular cortical bone loss in SLE patients with 2D panoramic radiography and 3D Cone Beam Computerized Tomography (CBCT)

MATERIALS AND METHODOLOGY

This study is approved by the Research Ethics Committee in Universitas Sumatera Utara. The cross-sectional study was conducted in the Internal Medicine Installation at Hasan Sadikin Hospital in 2014. Panoramic radiography and CBCT measurements were obtained in Oral and Dental Hospital Universitas Padjajaran, Bandung from 31 SLE patients who consumed corticosteroid for at least 2 years.

2D panoramic radiography and 3D CBCT were obtained in standing or on wheelchair conditions using Pax Duo 3D Plus with 18 and 30 seconds of scanning time for CBCT and panoramic radiography

respectively, then 15 and 24 seconds of exposure time for CBCT and panoramic radiography respectively. The voxel size was 0.12 mm. The radiograph was set to Digital Imaging focuses on mandibular cortical.

MCI can be used to identify the boundary of the mandibular distal cortex to mental foramen in the radiography. MCI in panoramic radiography is assessed by observing mandibular in antegonial notch area measured from mental foramen bilateral. The estimated value for the visual of cortical bones is

based on the changes of inferior cortex in panoramic radiography by using Klemetti index (Figure 1) as follows:⁶

C1 - endosteal from inferior cortex are fines at both ends

C2 - endosteal margin shows semilunar damages or shows the formation of remaining cortical endosteal

C3 - cortex is clearly porous with the remaining dense endosteal

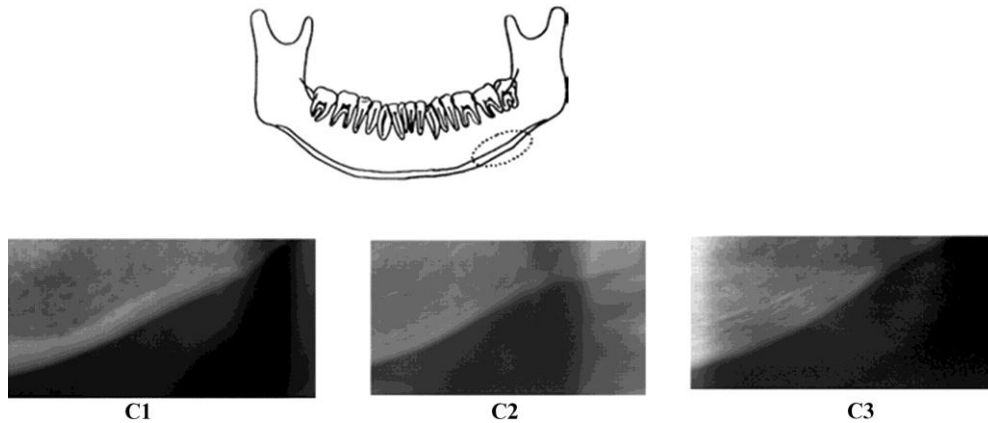


Figure 1: Panoramic Radiography based on Klemetti index.

C1: The sharpness of cortex endosteal margin in both ends, C2: Semilunar damages (lacunar resorption) in the endosteal margin or at one or both sides of the remaining endosteal cortex, C3: The remaining severe and porous endosteal cortical.

Figure 2a to 2c show the level of cortical bone loss which is classified as follow: mild cortical bone loss (1.0 – 1.9 mm); moderate cortical bone loss (2.0 – 2.9 mm); severe cortical bone loss (>3 mm).

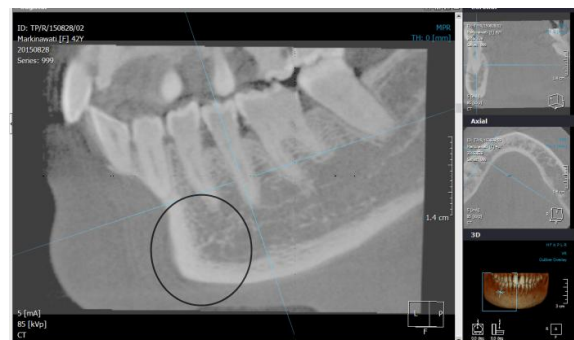


Figure 2b: CBCT image of moderate cortical bone loss.

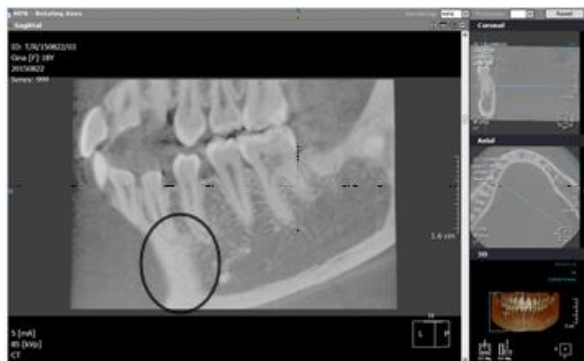

Figure 2a: CBCT image of mild cortical bone loss.

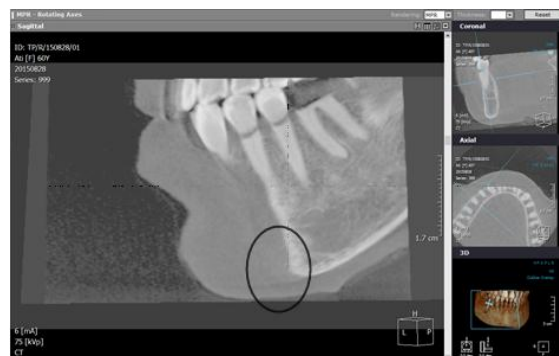

Figure 2c: CBCT image of severe cortical bone loss.

Univariate analysis was conducted to obtain a specific characteristic of cortical bone loss measurement using 2D panoramic radiography and 3D CBCT using T and McNemar tests. Next, the multivariate analysis was done to get data of treatment period, corticosteroid dosage and the pattern of cortical bone loss in patients using the two methods. The statistical analysis using SPSS version 15.0 with $p < 0.05$ window as statistically specific.

RESULT

Table 1 shows patients at a range of age of 17 to 60 years old with a mean age of 37.65 ± 10.79 years old. The patients are diagnosed with SLE for 2 to 20 years. The average dosage of methylprednisolone consumed is $5.23 \text{ mg} \pm 4.37 \text{ mg}$.

Table 1: Characteristic of Research Subject

Characteristic	Mean \pm SD	Min.	Max.
Age	37.65 ± 10.79	17	60
Age infected (years)	8.00 ± 4.97	2	20
Dosage (mg)	$5.23 \text{ mg} \pm 4.37 \text{ mg}$	2	16

Cortical bone loss diagnosis in patients using 2D panoramic radiography and 3D CBCT is shown in Table 1. To control the occurrence of errors, all measurements using panoramic radiography and CBCT were analyzed. Both panoramic radiography and CBCT measurement shows no significant difference to average cortical bone height on the right and left sides with $p = 0.899$ and $p = 0.890$ respectively (Table 2).

Table 2: The validity and reliability of cortical bone loss examination in 2D panoramic radiography and 3DCBCT.

Measurement		$\bar{x} \pm sd$	p
2D Panoramic radiography	Right	$2.64 \pm 0,41$	0.899*
	Left	$2.65 \pm 0,50$	
3D CBCT	Right	$2.57 \pm 0,53$	0.890*
	Left	$2.56 \pm 0,54$	

Table 3: Cortical bone loss based on 2D panoramic radiography and 3D CBCT

		CBCT			Total	P	κ
		T1	T2	T3			
Panoramic Radiography	C1	1 (3.2%)	0 (0.0%)	0 (0.0%)	1 (3.2%)	0.211*	0.193
	C2	3 (9.7%)	15 (48.4%)	4 (12.9%)	22 (71.0%)		
	C3	0 (0.0%)	5 (16.1%)	3 (9.7%)	8 (25.8%)		
		4 (12.9%)	20 (64.5%)	7 (22.6%)	31 (100%)		

McNemarBowker test shows no significant difference in the loss of cortical bone between panoramic radiography and CBCT tests although the Kappa coefficient was low ($\kappa = 0.193$). Table 3 shows that CBCT is more sensitive to detect cortical bone loss where CBCT shows a severe cortical bone loss while in panoramic radiography shows an only moderate loss.

The relationship between the two variables does not show a significant association in pano-

ramic radiography while 3D CBCT shows a significant relation with corticosteroid dosage ($p = 0.026$) (Table 4). With 3D CBCT, bone loss is 3.1 times more likely than in panoramic radiography if corticosteroid is consumed (0.096 to 0.007).

Table 4: The comparison of mandibular cortical bone loss based on 2D panoramic radiography and 3D CBCT

	Independent Variable	Non-standardized Coefficients			95% CI for B	
		B	Std. Error	P Value	Lower Bound	Upper Bound
Panoramic radiography	Constant	2.963	0.285	0.001	2.378	3.548
	Treatment period	0.008	0.016	0.639	-0.025	0.040
	Dosage	-0.029	0.017	0.103	-0.065	0.006
	Age	-0.006	0.007	0.398	-0.021	0.008
CBCT	Constant	3.115	0.360	0.001	2.377	3.853
	Treatment period	-0.021	0.020	0.297	-0.062	0.020
	Dosage	-0.052	0.022	0.026*	-0.096	-0.007
	Age	-0.003	0.009	0.752	-0.021	0.015

* $P < 0.05$: significant

DISCUSSION

SLE is a chronic autoimmune disease that attacks some systems in the body. The body produces several types of antibody, especially in cortical bones. The immunology changes in SLE are the complexity deposition and the further damages in the connective tissues and several organs, especially the density of the bone mineral.^{12,17} Although genetic component is important in osteoporosis regarding the susceptibility attached to the population towards SLE, it was further explored and suggested to be under the different social demography based on the lifestyle in the third and fourth century.¹⁵ Cortical bone has important roles in determining the strength of mandibular bone. The loss of strength is due to the imbalance of intracortical and endocortical remodeling which produces cortical porosity and depletion.

Some studies that related analyze osteoporosis as the cause of fracture and how to reduce the susceptibility to fracture was required. The anatomy indicator of mandibular, especially angulus cortical mandibular in panoramic radiography is useful to evaluate the density of bone mineral for women based on their age. The quantity and quality of bone mineral have become a big problem for the health. In dental elderly patients (60 – 88 years old), there are significant differences due to gender, dental status and mandibular cortical index between patients with or without osteoporosis.¹³ The differences between cortical bones varied either in maxillary or mandibular regions. However, the mandibular cortical thickness should be considered in orthodontic tooth movement of the patient with osteoporotic and other systemic diseases.¹⁹

In this research, the layers of angulus cortical in mandibular are not able to be detected before 15 years old. Osteoporosis can affect all the bones in the body to influence the loss of cortical bones significantly while the thickness of angulus cortex decreased significantly post-menopause.^{14,20} Although there is no correlation in cortical bones based on panoramic radiography, there is a moderate correlation in 3D CBCT.

Table 4 shows that high usage of corticosteroid leads to the loss of lower cortical bones, with significant correlation with methylprednisolone and the loss of cortical bones ($p = 0.037$). Every 10 mg increase of methylprednisolone consumption shows 0.52 mm loss of bones. This condition is known as the continuous effect of medicine which points at bones, growth factors and inflammatory mediators which also affect the loss of cortical bone. Cortical and trabecular bones' mass decreases in perimenopause patients with lupus compared to healthy women at the same age. Moreover, the loss of bones by consuming corticosteroid equals the consumption of other medicine, for instance, glucocorticoid.^{9,21-22} Several studies show 98% reproducibility of the mandibular cortical index in which a significant relationship was observed at endosteal residues at the sides of mandibular cortical based on 2D panoramic radiography and 3D CBCT ($p = 0.890$). However, the effect of corticosteroid shows a significant loss of cortical bones in 3D CBCT than in 2D panoramic radiography.

The advancement of radiography diagnostic refers to the detection of micro-architecture of cortical bones as the projection of the transition of trabecular bone to micro-architecture which is re-

lated to the remodeling process. The strategies in anticipating the response of bone losses related to the development of diseases involve an effective unknown disease treatment, the modification of risk factors known to cause osteoporosis, the basis of effective usage of corticosteroid and other types of pharmacological treatment.²³

It can be concluded that there was a significant relationship in the loss of mandibular cortical

bone analyzed by 3D CBCT compared to panoramic radiography of SLE patients in Hasan Sadi-kin Hospital. A further study is required to understand before SLE multi-pathogenic process. This is a fundamental research in evaluating the severity of bones lose and environment factor in order to obtain proper diagnosis in treatment patient with certain systemic disorder.

REFERENCE

- Maidhof W, Hilas O. Lupus: an overview of the disease and management options. *PT.* 2012; 37 (4): 240-6.
- Sebastiani G. D, Prevele I, Iuliano A, Minisola G. The importance of an early diagnosis in systemic lupus erythematosus. *IMAJ.* 2016; 18(3-4): 212-5.
- Yoga K I, Kusworini H, Linda KW, Lanayati H, Zuljasri A, Handono K, Hermansyah, et al. Rekomendasi perhimpunan reumatologi Indonesia untuk diagnosis dan pengelolaan lupus eritematosus sistemik. *Perhimpunan Reumatologi Indonesia,* 2011: 1-54
- Taguchi A, Asano A, Ohtsuka M, Nakamoto T, Suei Y, Tsuda M; et al. Observer performance in diagnosing osteoporosis by dental panoramic radiographs: results from the osteoporosis screening project in dentistry (OSPD). *Bone* 2008; 43(1): 209-13.
- Taguchi A, Tsuda M, Ohtsuka M, Kodama I, Sanda M, Nakamoto T; et al. Use of dental panoramic radiographs in identifying younger postmenopausal women with osteoporosis. *Osteoporos-Int* 2006; 17(3): 387-94.
- Suma MS, Sujatha GP, Ashok L, Chaurasia A. Mandibular Cortex Index as a Predictor of Skeletal Osteoporosis-panoramic radiograph study. *Int J of Maxillofac Imaging* 2016; 2(2): 40-45.
- Kribbs PJ. Comparison of mandibular bone in normal and osteoporotic women. *J Prosthet Dent* 1990; 63(2): 218-22.
- Khojastehpour L, Mogharrabi S, Dabbaghmanesh MH, Nasrabadi NI. Comparison of the mandibular bone densitometry measurement between normal, osteopenic and osteoporotic postmenopausal women. *J Dent* 2013; 10(3): 203-9
- Houssiau FA, Lefebvre C, Depresseux G, Lambert M., Devogelaer JP. Nagant de Deuxchaisnes C. Trabecular and cortical bone loss in systemic lupus erythematosus. *Br J Rheumatol* 1996; 35(3), 244-7.
- J. Teichmann, U. Lange, H. Stracke K. Federlin R. G. Bretzel. Bone metabolism and bone mineral density of systemic lupus erythematosus at the time of diagnosis. *Rheumatol Int* 1999; 18(4): 137-40
- Cakur B, Dagistan S, Sahun A, Harolrli A. Reliability of mandibular cortical index and mandibular bone mineral density in the detection of osteoporotic women. *Dentomaxillofac Radiol* 2009; 38(5): 255-61
- Fabbri C, Fuller R, Bonfá E, Guedes LK, D'Alleva PS, Borba EF. Periodontitis treatment improves systemic lupus erythematosus response to immunosuppressive therapy. *Clin Rheumatol* 2014; 33(4): 505-9.
- Hastar E, Yilmaz HH, Orhan H. Evaluation of mental index, mandibular cortical index and panoramic mandibular index on dental panoramic radiographs in the elderly," *Eur J Dent* 2011; 5(1): 60-67.
- Cocojaru M, Cocojaru IM, Silosi I, Doina C. Manifestations of Systemic Lupus Erythematosus. *Maedica* 2011; 6(4): 330-6.
- Osio-Salido E, Manapat-Reyes H. Epidemiology of systemic lupus erythematosus in Asia. *Lupus* 2010; 19(12): 1365-73
- Taguchi A, Tanimoto K, Suei Y, Wada T. Tooth loss and mandibular osteopenia. *Oral Surg Oral Medi Oral Pathol Oral Radiol Endod* 1995; 79(1): 127-32.
- Sete MRC, Figueredo CMD, Sztainbok F. Periodontitis and systemic lupus erythematosus. *Rev Bras Reumatol* 2016; 56(2): 165-70.
- Bala Y, Zebaze R, Seeman E. Role of cortical bone in bone fragility. *Curr Opin Rheumatol* 2015; 27(4): 406-13
- Farnsworth D, Rossouw PE, Ceen RF, Buschang PH. (2011). Cortical bone thickness at common miniscrew implants placement sites. *Am J Orthod and Dentofacial Orthop* 2011; 139(4): 495-503.
- Jowitt N, Macfarlane T, Devlin H, Klemetti E, Horner K. The reproducibility of the mandibular cortical index. *Dentomaxillofac Radiol* 1999; 28(3): 141-4.
- Boyanov M, Robeva R, Popivanov P. Bone mineral density changes in women with systemic lupus erythematosus. *Clin Rheumatol* 2003; 22(4-5): 318-23.

22. Inge-Margrethe G, Tore KK, Glenn H, Gunnar H. Bone mineral density in systemic lupus erythematosus: comparison with rheumatoid arthritis and healthy controls. *Ann Rheum Dis* 2000; 59(2): 110–15.
23. Sinigaglia L, Varenna M, Binelli L, Zucchi F, Ghiringhelli D, Fantini F. Bone mass in systemic lupus erythematosus. *Clin Exp Rheumatol* 2000; 18(21): 527-34