

Effect Difference of *Centella asiatica* Leaves Methanolic Extract on Scratch and Incision of Dimethylbenz [A] Anthracene (DMBA) Induced Dysplasia Incidence

Ahyar Riza^{*1}, Denny Satria³, Nurhalijah², Iluh Wulandani²

¹Department of Oral and Maxillofacial Surgery Faculty of Dentistry, Universitas Sumatera Utara Medan, 20155, Indonesia

²Faculty of Dentistry, Universitas Sumatera Utara Medan, 20155, Indonesia

³Departement of Pharmaceutical Biology, Faculty of Pharmacy, Univesitas Sumatera Utara, Medan, 20155, Indonesia

*Author: ahyar.riza@usu.ac.id

ARTICLE INFO

Article history:

Received 22 February 2022

Revised 22 February 2023

Accepted 27 February 2023

Available online 25 July 2023

E-ISSN: [2615-854X](#)

P-ISSN: [1693-671X](#)

How to cite:

Ahyar Riza, Denny Satria, Nurhalijah, Iluh Wulandani
Effect Difference of *Centella asiatica* Leaves Methanolic Extract on Scratch and Incision of Dimethylbenz [A] Anthracene (DMBA) Induced Dysplasia Incidence. Dentika Dental Journal 2023; 26(1): 29-33

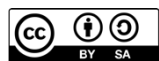ABSTRACT

Oral epithelial dysplasia is an abnormal cytology and architectural change that can develop into oral malignancy with a high mortality rate. *Centella asiatica* leaves possesses the potential to act as a chemopreventive agent and is known for its relative safety and ease of obtainability. Therefore, this study aimed to determine effect of *Centella asiatica* leaves extract on dysplasia induced by dimethylbenz [a] anthracene (DMBA) with scratch and incision. The *in vivo* study involved 21 Wistar rats (*Rattus norvegicus*) divided into three groups. The groups received 2% *Centella asiatica* leaves methanolic extract orally by force-feeding once daily, from day 1 until day 61. At day 29, dysplasia was induced by scratching the buccal mucosa of each rat using a syringe containing 0.5% DMBA. This was conducted with incision 1 cm in length and half angle in depth, 1 cm in length and 1 mm in depth, and 2 cm in length and 1 mm in depth for groups 1, 2, and 3. Furthermore, the rats were sacrificed, and histopathological analysis was performed using hematoxylin-eosin staining. The degree of dysplasia was assessed using the WHO 2017 classification, and the data were analyzed using the Mann-Whitney test. Meanwhile, the statistical test showed significant difference in the degree of dysplasia for all groups. It can be concluded that *Centella asiatica* methanolic extract leaves possesses the potential to be a chemopreventive agent in reducing dysplasia levels.

Keywords: *Centella Asiatica* Leaves, Dysplasia, Dimethylbenz [a] Anthracene

ABSTRAK

Displasia epitel rongga mulut merupakan kelainan sitologi dan arsitektural yang dapat berkembang menjadi keganasan rongga mulut dengan angka kematian yang tinggi. *Centella asiatica* merupakan tanaman yang memiliki potensi sebagai agen kemopreventif yang diketahui relatif lebih aman dan mudah diperoleh. Penelitian ini bertujuan untuk mengetahui perbedaan pengaruh ekstrak daun *Centella asiatica* terhadap kejadian displasia yang diinduksi dimethylbenz [a] anthracene (DMBA). Dalam penelitian *in vivo* ini, menggunakan 21 ekor tikus Wistar (*Rattus norvegicus*) yang dibagi menjadi tiga kelompok. Kelompok diberi ekstrak metanol 2% *Centella asiatica* secara oral satu kali sehari mulai hari ke 1 sampai hari ke-61. Pada hari ke-29 induksi displasia dilakukan dengan cara menggores mukosa bukal dari setiap tikus



This work is licensed under a Creative Commons Attribution-ShareAlike 4.0 International.
<http://doi.org/10.32734/dentika.v26i1.8395>

menggunakan spuit yang mengandung 0,5% DMBA dengan panjang 1 cm dan kedalaman setengah bevel (kelompok 1), panjang 1 cm dan kedalaman 1 mm (kelompok 2), panjang 2 cm dan kedalaman 1 mm (kelompok 3). Tikus dikorbankan pada setiap kelompok untuk pemeriksaan histopatologi dengan pewarnaan hematoksin-eosin. Klasifikasi WHO 2017 digunakan untuk menilai derajat displasia. Data dianalisis menggunakan uji *Mann-Whitney*. Hasil uji statistik menunjukkan terdapat perbedaan derajat displasia pada seluruh kelompok. Kesimpulan dari hasil penelitian ini adalah ekstrak metanol daun *Centella asiatica* berpotensi sebagai agen kemopreventif dalam menurunkan derajat displasia.

Kata kunci: Daun *Centella Asiatica*, Dysplasia, Dimethylbenz [a] Anthracene

1. Introduction

Oral squamous cell carcinoma is the 8th most prevalent form of cancer worldwide, accounting for 90% of all malignancies within the oral cavity. In West Java Province, Indonesia, 95 new oral squamous cell carcinoma cases were reported within a year.[1]

The onset of malignancy is usually preceded by dysplasia in stratified squamous epithelium, which refers to the abnormal growth of size, shape, and organization of mature cells. These changes potentially develop into oral cavity malignancy in chronic inflammatory conditions, but dysplasia can become normal cells with good monitoring and treatment.[2],[3]

In general, cancer is treated by surgery, chemotherapy, or radiotherapy. The drawbacks of these treatments are toxic side effect in normal tissues and cancer cell resistance, which can cause increased discomfort.[4],[5] Therefore, efforts are needed to reduce the prevalence by developing chemopreventive agents that are non-toxic, relatively safe, harmless, and easy to obtain.[5] Study by Umadevi et al. in 2013 showed that natural compounds capable of inhibiting or killing cancer cells showed their potential as anti-cancer,[5],[6] such as *Centella asiatica* leaves.[2]

The plant grows in tropical areas of Asian countries and can be used as traditional medicine. It contains several active ingredients such as triterpenoids (asiatic acid, madecassic acid, asiaticoside), flavonoid derivatives (quercetin, kaempferol, patuletin, and rutin), vitamins, minerals, polysaccharides, sterols, and phenolic acids. The South African Journal of Botany, in 2017, regarding the plant extract, analyzed its potential as an antioxidant, antimicrobial agent, collagen synthesis agent, wound healer, and anti-cancer. Most studies reported asiaticoside as an active ingredient that produces this effect. Yingchun et al. (2019) stated that asiaticoside could produce anti-cancer effect on multiple myeloma.[2],[3] According to Zheng and Lu (2011), the compound has a high solubility in methanol, hence, it is a good solvent for extracting *Centella asiatica* leaves.[2],[3],[6]

Several studies have been conducted regarding the chemopreventive agents of other herbal plants against precancerous lesions and oral cancer. However, there are few results on *Centella asiatica* leaves as an anti-cancer for oral dysplasia. Based on this description, analyzing the different effect of *Centella asiatica* leaves methanolic extract treatment on scratch and incision of dimethylbenz [a] anthracene (DMBA) induced dysplasia was necessary.

2. Materials and Methods

This study was conducted on 21 male Wistar rats at the Focus Laboratory, following the ethical approval obtained from the USU FMIPA Animal Research Ethics Committee, no.0162/KEPH-FMIPA/2021. *Centella asiatica* leaves were sourced from Salakmalang, Banjarharjo, Kalibawang, Kulon Progo, and Yogyakarta. The samples used were 8 weeks old male Wistar rats (*Rattus norvegicus*) with an average body weight of 200-300 grams and healthy. Healthy rats were characterized by active movement, clear eyes, clean fur, had not been treated before, and had healthy oral mucosa, which was clinically pink, indicating good blood supply with a shiny surface. A total of 21 samples were used in this study, which was divided into 3 groups. The first group

was treated with *Centella asiatica* leaves methanolic extract with DMBA streaking, while the second was treated with *Centella asiatica* leaves methanolic extract with a DMBA incision. The third group was treated with *Centella asiatica* leaves methanolic extract with a DMBA stroke length of 2 cm. The leaves were dried using a drying cabinet and mashed with a blender. Subsequently, the leaves were put into a plastic container and tightly sealed. *Centella asiatica* leaves were extracted and evaporated using the maceration method and rotary evaporator, then dried in an oven to remove the remaining methanol.

Male Wistar rats were acclimatized before being treated for 1 week. *Centella asiatica* leaves methanolic extract treatment was administered orally with a concentration of 2% and a dose of 100 mg/ kg of body weight using a gastric probe. This treatment was performed once a day every morning after feeding the rats, and the process lasted for 61 days.

At day 29, each rat in the treatment group was anesthetized using ketamine hydrochloride intraperitoneally at 10 mg/kg body weight. The left buccal mucosa of each rat in treatment group 1 was then scratched using a 27 G syringe containing 100 µg of 0.5% DMBA with 1 cm in length and half bevel in depth. In group 2, the treatment involved making an incision of 1 cm in length and 1 mm in depth using a scalpel and a number 11 blade filled with 100 µg DMBA 0.5%. In treatment group 3, the left buccal mucosa of the rats was scratched using a 27 G syringe containing 100 µg of 0.5% DMBA with 2 cm in length and half-bevel in depth. Furthermore, DMBA exposure was carried out 3 times a week for 1 month. On day 61, the experimental animals were sacrificed for sampling, and a histopathological examination was performed with hematoxylin-eosin (HE) staining to determine effect of methanolic extract on dysplasia incidence. The tissue was observed under a light microscope, and dysplasia assessment was based on WHO 2017 score. A score of 1 was observed, indicating mild dysplasia characterized by slight abnormalities in the nucleus, as well as cytological and architectural changes limited to the lower 1/3 portion of the total epithelial thickness from the basal to the parabasal layer. The nuclei exhibited mild abnormality and showed no abnormal mitoses, but keratosis and chronic inflammation were reported. A score of 2 was observed, indicating moderate dysplasia characterized by changes that involve 2/3 of the total epithelial thickness from the basal to the middle spinosum layer. Furthermore, there were more variations in nuclei abnormalities, and mitoses occurred in the parabasal and middle layers, which were within normal limits. A score of 3 was observed, indicating severe dysplasia characterized by changes that exceeded 2/3 of the basal layer, with obvious nuclear abnormalities, abnormal mitotic cells, and squamous keratin or horn pearls. The data were then analysed statistically using the Mann-Whitney test.

3. Results

During the 61 days of the study process, of the 21 male Wistar rats, 19 rats survived until the end of the study and 2 rats that died due to rat susceptibility factors and genetic mutations. Each rat was treated according to the group, then dysplasia level was assessed based on the 2017 WHO score. Of these 3 groups, the mice in the group 1 showed lower dysplasia than group 2 and 3. The dysplasia in this study showed structural and architectural abnormalities found in the left buccal mucosa of rats, such as abnormal nucleus shape and size, hyperchromatic nucleus, increased nuclear-to-cytoplasmic ratio, and the presence of abnormalities in epithelial tissue with loss of basal cell polarity. In this case, *Centella asiatica* leaves are able to inhibit the dysplasia level to a more severe level. The average results of dysplasia level in each group with hematoxylin eosin staining can be seen in Figure 1, 2 and 3.

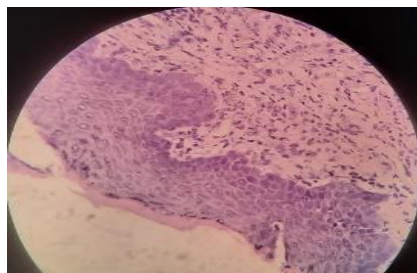


Figure 1. Histopathological view of mild dysplasia level of group 1

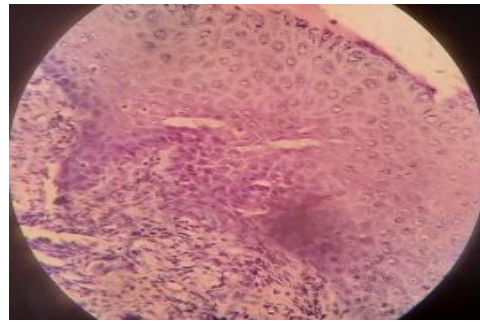


Figure 2. Histopathological view of mild dysplasia level of group 2

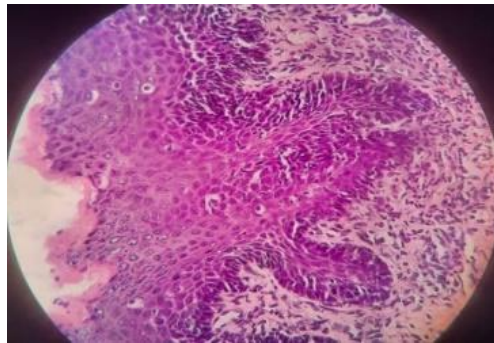


Figure 3. Histopathological view of mild dysplasia level of group 3

Based on the results of the normality test using the Shapiro-Wilk test, it is known that the data was not normally distributed ($p = 0.001$). Therefore, data analysis was continued using the Mann Whitney test to see the differences between the 2 groups. This test results showed that there is significant difference between group 1 and group 2 with $p \text{ value} = 0.035 > 0.05$, between group 1 and 3 with $p \text{ value} = 0.019 > 0.05$, between group 2 and 3 with $p \text{ value} = 0.041 > 0.05$ (Table 1).

Table 1. Mann Whitney test results

	Group	N	Mean rank	Sum of rank	p- value
Displasia	<i>Centella asiatica</i> leaves methanolic extract and DMBA scratch	6	5.00	30.00	0.035
	<i>Centella asiatica</i> leaves methanolic extract and 1 cm of DMBA incision	7	8.71	61.00	
Displasia	<i>Centella asiatica</i> leaves methanolic extract and DMBA scratch	6	4.25	25.50	0.019
	<i>Centella asiatica</i> leaves methanolic extract and 2 cm of DMBA scratch DMBA	6	8.75	52.50	
Displasia	<i>Centella asiatica</i> leaves methanolic extract and 1 cm of DMBA incision	7	5.93	41.50	0.041
	<i>Centella asiatica</i> leaves methanolic extract and 2 cm of DMBA scratch DMBA	6	8.25	49.50	

4. Discussions

This study commenced with the production of a concentrated extract of *Centella asiatica* leaves. The extraction procedure was carried out by maceration using methanol as solvent. Maceration is most widely used because it is simple and can avoid damage to thermolabile compounds since heat is not required. Furthermore, the tools and processing methods are simple, easy to obtain, and relatively low costs.[7-9]

Carcinogenesis goes through the initiation, promotion, and progression phases. It begins with cellular changes due to exposure to carcinogens, such as ultraviolet light, viruses, and exposure to cigarette smoke and other substances, resulting in DNA damage or gene mutations. The study was initiated by producing a concentrated extract derived from the leaves of *Centella asiatica* leaves.[10] Therefore, DMBA is used as a carcinogenic substance administered as a test for dysplasia incidence. DMBA can produce carcinogenic dihydrodiol epoxides that mediate malignant transformation processes by inducing DNA damage. This causes the release of reactive oxygen species (ROS) or other types of reactive chemicals, resulting in severe damage to healthy or normal cells.[7],[8] DMBA compounds can be found in the environment as combustion products, such as air pollution, exhaust fumes, cigarette smoke, diesel fuel, and baked goods.[9-11]

The study shows that employing *Centella asiatica* leaves methanolic extract as a chemopreventive agent demonstrates potential efficacy against dysplasia incidence caused by scratch and incision of DMBA. Therefore, the treatment of methanolic extract reduces dysplasia level in the model of different severity.[12] This is because the leaves contain significant active compounds, namely triterpenoids, and flavonoids, that exhibit anti-proliferative or cytotoxic activity against various cancer cells. These compounds function as antioxidants, improving the immune system and promoting overall human health. Triterpenoid consists of asiaticoside, madecassosic acid, and asiatic acid.[2],[3],[12],[13]

These results were similar to the report of Hashim et al. (2011), where the antioxidant content in *Centella asiatica* leaves at 84% was comparable to grape seed extract (83%) and vitamin C at 83% and 88%, respectively. Many experimental reports prove that extract has antioxidant activity, and asiaticoside plays a major role in increasing this property.[14],[15]

Several studies have shown that asiaticoside can improve the sensitivity of human oral epithelial cancer cells by increasing intracellular ROS and enhancing apoptotic pathways.[16] Decreased mitochondrial membrane potential is a common phenomenon of apoptosis in cancer cells that results in the release of genes to stimulate programmed cell death. In addition, the cell cycle transition from G1 to S is influenced by many genes, such as CDK4/6 and cyclin D1. A study has shown that downregulating CDK4/6 expression and cyclin D1 leads to cell cycle arrest in the G1 phase. This can explain the asiaticoside mechanism, which can reduce dysplasia level.[16]

This study found that the treatment of *Centella asiatica* leaves with methanolic extract decreased dysplasia. Meanwhile, the treatment of methanolic extract with a smaller DMBA stroke length and shallower depth of induction resulted in a lower level of dysplasia.

References

- [1]. Sjamsudin E, Maulina T, Cipta A, Iskandarsyah A, Hardianto A, Nandini M, et al. Assessment of oral cancer pain, anxiety, and quality of life of oral squamous cell carcinoma patients with invasive treatment procedure. *Oral Maxillofac Surg.* 2018; 22(1): 83–90.
- [2]. Azis HA, Taher M, Ahmed AS, Sulaiman WMAW, Susanti D, Chowdhury SR, et al. In vitro and In vivo wound healing studies of methanolic fraction of *Centella asiatica* extract. *South African J Bot.* 2017; 108: 163–74.
- [3]. Yingchun L, Huihan W, Rong Z, Guojun Z, Ying Y, Zhuogang L. Antitumor activity of asiaticoside against multiple myeloma drug-resistant cancer cells is mediated by autophagy induction, activation of effector caspases, and inhibition of cell migration, invasion, and stat-3 signaling pathway. *Med Sci Monit.* 2019; 25: 1355–61.
- [4]. Li X, Zhang H, Wang Y, Sun S, Shen Y, Yang H. Silencing circular RNA hsa_circ_0004491 promotes metastasis of oral squamous cell carcinoma. *Life Sci.* 2019; 239: 116883.
- [5]. Adelina R, Oktoberia IS, Intan PR. *Annona muricata*'s leaves ethanolic extract enhance p53 expression in rat hepatic cells induced by dimethylbenz(a)anthracene (DMBA). *Indones J Cancer Chemoprevention.* 2013; 4(1): 483.
- [6]. Hamid IS, Rai Widjaja NM, Damayanti R. Anti-cancer activity of *Centella asiatica* leaves extract in

- benzo(a)pyrene-induced mice. *Int J Pharmacogn Phytochem Res.* 2016; 8(1): 80–4.
- [7]. Singh S, Singh J, Chandra S SF. Prevalence of oral cancer and oral epithelial dysplasia among North Indian population: A retrospective institutional study. *J oral Maxillofac Pathol.* 2020; 24(1): 87–92.
- [8]. Nurlaily A, Noor BAR, Musalmah M. Comparative antioxidant and anti-inflammatory activity of different extracts of *Centella asiatica* (L.) Urban and its active compounds, asiaticoside and madecassoside. *Med Heal.* 2012; 7(2): 62–72.
- [9]. Mukhriani. Ekstraksi, pemisahan senyawa, dan identifikasi senyawa aktif. *J Kesehat.* 2014; 7(2): 361–7.
- [10]. Singh D, Mishra M, Gupta M et al. Nitric Oxide radical scavenging assay of bioactive compounds present in methanol Extract of *Centella asiatica*. *Int J Pharm Pharm Res.* 2012; 23: 42-4
- [11]. Maulina T, Widayanti R, Hardianto A, et al. The usage of curcumin as chemopreventive agent for oral squamous cell carcinoma: An experimental study on Sprague-Dawley rat. *Integr Cancer Ther.* 2019; 18(1): 1–7.
- [12]. Putra AAB, Bogoriani NW, Diantariani NP. Ekstraksi zat warna alam dari bonggol tanaman pisang (*Musa paradisiaca* L.) dengan metode maserasi, refluksm dan sokletasi. *J Kim.* 2020; 14(41): 94–100.
- [13]. Putra AAB, Bogoriani NW DN. Ekstraksi zat warna alam dari bonggol tanaman pisang (*Musa paradisiaca* L.) dengan metode maserasi, refluksm dan sokletasi. *J Kim.* 2020; 14(41): 94–100.
- [14]. Wibowo AE, Sriningsih S, Wuyung PE, Ranasasmita R. The Influence of DMBA (7,12-dimethylbenz[a]anthracene) Regimen In The Development of Mammary Carcinogenesis on Sprague Dawley Female Rat. *Indones J Cancer Chemoprevention.* 2010; 1(1): 60.
- [15]. Naido DB. An in vitro investigation into the anti-proliferative and anti-inflammatory properties of *Centella asiatica* (Linnaeus) Urban (leaf) and *withania Somnifera* (Linnaeus) dunal (root) extract. Thesis. Glenwood, Durban: University of KwaZulu-Natal, 2017: 1–14.
- [16]. Juananda D, Sari DCR, Ar-Rochmah M, Arfian N, Romi MM. Ethanol Extracts of *Centella asiatica* (L.) Urb. Leaf Increase Superoxide Dismutase-2 (SOD-2) Expression on Rat Cerebellar Purkinje Cells After Chronic Stress. *J Ilmu Kedokt.* 2018; 11(2): 24.