

## Study on Acute Oral Toxicity of Ethanolic Extract of *Annona squamosa* Leaves in Mice (*Mus musculus*)

Andini Dita Utami<sup>1</sup>, Khairunnisa<sup>1\*</sup>, Marianne<sup>1</sup>

<sup>1</sup>Faculty of Pharmacy, Universitas Sumatera Utara,  
Padang Bulan, Medan 20155, Indonesia

**Abstract.** The aims of this study were to determine the potential for acute oral toxicity of ethanolic extract of *A. squamosa* leaves with LD<sub>50</sub> and the histopathological changes in liver and kidney of mice. This research used experimental method as per fixed dose method. The number of animals used in this research were 20 female mice. The study was divided into 2 steps, there were sighting and main studies. The control group was given Na-CMC 0.5%, the treatment groups were given ethanolic extract of *A. squamosa* leaves with doses of 5, 50, 300, 2,000 and 5,000 mg/kg bw. The results showed that the ethanolic extract of *A. squamosa* leaves with doses of 2,000 and 5,000 mg/kg bw did not show any toxicity signs. At a dose of 5,000 mg/kg bw caused hydropic degeneration, necrosis hepatocyte, glomerular atrophy, and tubular dilatation. There was no mortality was observed. It was estimated that LD<sub>50</sub> of ethanolic extract of *A. squamosa* leaves was higher than 5,000 mg/kg bw and the extract were practically non-toxic.

**Keywords:** Acute toxicity, *Annona squamosa*, Ethanolic extract

**Abstrak.** Tujuan penelitian ini adalah untuk mengetahui potensi toksisitas akut oral ekstrak etanol daun srikaya (*Annona squamosa*) dengan menentukan LD<sub>50</sub> dan perubahan histopatologi hati dan ginjal mencit. Penelitian ini menggunakan metode eksperimental yaitu metode fixed dose. Hewan yang digunakan pada penelitian ini berjumlah 20 ekor mencit betina. Uji dibagi menjadi dua tahapan, yaitu uji pendahuluan dan uji utama. Kelompok kontrol diberi Na-CMC 0,5%, kelompok uji diberi ekstrak etanol daun srikaya (*A. squamosa*) dengan dosis 5, 50, 300, 2000 dan 5000 mg/kg bb. Hasil penelitian menunjukkan bahwa ekstrak etanol daun srikaya (*A. squamosa*) dosis 2000 dan 5000 mg/kg bb tidak menimbulkan gejala toksik pada mencit. Pada dosis 5000 mg/kg bb menyebabkan degenerasi hidropik, nekrosis pada hepatosit, atrofi glomerulus dan dilatasi lumen tubulus. Tidak terjadi kematian selama pengamatan. Diperkirakan bahwa LD<sub>50</sub> ekstrak etanol daun srikaya (*A. squamosa*) > 5000 mg/kg bb dan termasuk dalam kriteria praktis tidak toksik.

**Kata kunci:** Toksisitas akut, Srikaya, Ekstrak etanol

Received 02 June 2017 | Revised 26 October 2017 | Accepted 12 March 2018

\*Corresponding author at: Universitas Sumatera Utara, Medan, Indonesia

E-mail address: khairunnisa7@usu.ac.id

## 1. Introduction

Indonesia is known as one of the countries which has the biological diversity widely used as traditional medicine. Nowadays, even though a traditional medicine is widely used by people as self-medication, health professionals/doctors generally are still in doubt to prescribe or use the medicine. It is different in few countries such as China, Korea, and India, which integrate traditional medicine into the formal health care system. The main reason why health professionals doubt to prescribe or use traditional medicine because there is limited scientific evidence regarding the efficacy and safety of the medicines in humans [1].

*Annona squamosa* belongs to the family of Annonaceae. This plant grows as native in Netherlands Antillen and Exotic in Indonesia. It has a local names of delima bintang, sarikaya (Sumatra); sarikaya, srikaya, surikaya (Java); its foreign names are custard-apple, sugar apple, sweetsop (US, UK); raamaphal, shariiphaa, sitaphal (India). *A. squamosa* is a multipurpose tree with edible fruits and source of compounds medically and traditionally used for the treatment of diabetes [2], bacterial infection [3], hepatitis [4], hyperlipidemia [5], cytotoxic [6]. The previous research showed that the ethanol extract of *A. squamosa* leaves had IC<sub>50</sub> of 29.27 ppm which is a very powerful antioxidant category and effective as hepatoprotective.

In order to develop *A. squamosa* leaves as medicine, it is needed to study the efficacy and safety. Therefore, this study was carried out to evaluate acute oral toxicity of ethanolic extract of *A. squamosa* leaves with LD<sub>50</sub> and the histopathological changes in liver and kidneys of mice.

## 2. Materials and Methods

### 2.1. Plant identification

Fresh leaves of *A. squamosa* were collected in Medan, Indonesia. The sample was identified at the Herbarium Medanense University of Sumatera Utara and a voucher specimen was deposited there under the number 996/MEDA/2017.

### 2.2. Preparation of Extract

The collected plant material was dried at room temperature (30±3°C), pulverized, and finely sieved. The powder obtained (200g) was macerated in 1,000 ml of 96% of ethanol. The extract was filtered using Whatman filter paper and concentrated in an air circulating oven at 54°C to dry completely.

### 2.3. Experimental Animals

Twenty non pregnant nulliparous female Balb/c mice (*Mus musculus*) were used in this study. The experimental animals should be between 8 and 12 weeks old and their weight should fall in an interval within the mean weight ±20% (grams) during the experiment time.

#### 2.4. Acute Toxicity

An acute oral toxicity test used experimental method as per fixed dose method based on Regulation of Indonesia National Agency of Drug and Food Control No. 7 2014 for in vivo non-clinical toxicity testing.

#### 2.5. Preliminary Study

The purpose of the preliminary study was to obtain the appropriate starting dose of the ethanolic extract of the *A. squamosa* for the main study and to minimize the number of animals used. The mice were fasted for 3-4 hours except drinking water. The preliminary study was divided into 5 groups and single animal was used per group in the preliminary study (Table 1).

#### 2.6. Main Study

The main study consisted of the control and the treatment groups. The preliminary study indicated that ethanolic extract of *A. squamosa* leaves with doses of 5, 50, 300 and 2,000 mg/kg bw did not show mortality and any toxicity signs. Thus, the treatment group was provided the ethanolic extract of *A. squamosa* leaves with doses of 2,000 and 5,000 mg/kg bw. Each group consisted of 5 mice (Table 2). They were fasted for 3-4 hours except drinking water. Observations were made and recorded systematically every 30 minutes within 4 hours for 14 days after the extract provision. The LD<sub>50</sub> was then determined at the end of the experiment.

**Table 1.** The Preliminary Study

Group	Treatment
I	Control (Na-CMC 0.5%)
II	5 mg/kg bw
III	50 mg/kg bw
IV	300 mg/kg bw
V	2,000 mg/kg bw

**Table 2.** The Main Study

Group	Treatment
I	Control (Na-CMC 0.5%)
II	2,000 mg/kg bw
III	5,000 mg/kg bw

#### 2.7. Gross Pathologic Observations

Liver, right and left kidneys were visually observed for the color, shape and texture of organs.

## 2.8. Weighing of Organs

The liver and kidneys were washed with sodium chloride, dried with absorbent paper, and weighed to obtain the absolute organ weight.

$$\text{Relative organ weight} = \frac{\text{absolute organ weight}}{\text{body weight}}$$

## 2.9. Histopathological Study

Immediately after the death of the animals, the organs were fixed in 10% of formalin. After dehydration, clearing and infiltration, the tissues were embedded in paraffin wax and sectioned by microtome.

## 3. Results and Discussion

### 3.1. Observations of Toxicity Signs and Mortality

According to the preliminary study, an appropriate starting dose in main study was 2,000 mg/kg bw. The treatment was continued to the next dose if the animals were still alive at dose of 2,000 mg/kg bw [7]. The observations of toxicity signs and mortality at dose of 2,000 mg/kg bw can be seen in Table 3.

**Table 3.** Toxicity Signs and Mortality in the Control and Treatment Groups

Observations	30 min		4 hrs		24 hrs		48 hrs		1 week		2 weeks	
	C	T	C	T	C	T	C	T	C	T	C	T
Seizures	-	-	-	-	-	-	-	-	-	-	-	-
Diarrhea	-	-	-	-	-	-	-	-	-	-	-	-
Convulsions	-	-	-	-	-	-	-	-	-	-	-	-
Inactive	-	-	-	-	-	-	-	-	-	-	-	-
Death	-	-	-	-	-	-	-	-	-	-	-	-
Eyes	N	N	N	N	N	N	N	N	N	N	N	N
Skin	N	N	N	N	N	N	N	N	N	N	N	N
Abnormal movements	-	-	-	-	-	-	-	-	-	-	-	-

C = control group; T = treatment group; N = normal condition; (-) = negative

As shown in Table 3, mice treated with extract with the dose of 2,000 mg/kg bw did not show the signs of toxicity 4 hours after its oral administration. Additionally, after 48 hours no sign of observable toxicity was detected, so that the next group of animals at higher dose (5,000 mg/kg bw) should be administered. Generally, there are three options that will be taken in the main study may be dosed at higher, lower or stopped, depending on the presence of signs of toxicity and mortality [7]. The observation of toxicity signs and mortality at dose of 5,000 mg / kg bw can also be seen in Table 3. Based on Table 3, mice treated with the dose of 5,000 mg/kg bw also did not showed the signs of toxicity 4 hours after oral administration and in the last of

observation there was no mortality was recorded and also no signs of observable toxicity was detected during the experimental period.

### 3.2. Observation of Body Weight

Body weight of each animal was monitored before and after oral administration of the extract. The weighing was done as much as 7 times in 14 days. The changes in the animals' body weight were analyzed using a statistical product and service solution (SPSS) version 17. The observation of body weight can be seen in Table 4.

**Table 4.** Body Weight of the Control and Experimental Groups

Body weight (g) $\pm$ SD				
Control	2,000 mg/kg bw	p	5,000 mg/kg bw	p
28.911 $\pm$ 3.611	27.831 $\pm$ 2.554	0.260	28.486 $\pm$ 2.249	0.809

p = significance; SD = standard deviation

Based on the results of statistical analysis, the average weight of mice using one way ANOVA in Table 4, there was no significant difference in weight gained or weight loss of mice treated from the control group with significant level  $p > 0.05$ . Significant body weight loss may be one of the most sensitive indicators that an animal's condition is deteriorating. Body weight loss is usually associated with changes in food and water consumption, which should also be closely monitored by the animal care staff. In young animals that have not reached their adult body weight, an abnormal condition may be indicated by a reduced rate of weight gain when compared to the appropriately matched control animal, rather than an actual weight loss [7].

Main study showed that the oral dose of 2,000 mg/kg bw of the extract did not cause mortality or signs of toxicity to mice. According to the globally harmonized classification system for chemical substances and mixtures (GHS), the dose classify in category 5 or not classified. The dose up to 5,000 mg/kg bw, animals is still in normal condition, there are no toxicity signs or mortality. Therefore, oral intake of the ethanolic extract of *A. squamosa* leaves at dose less than or equal to 5,000 mg/kg bw was safe, but may not be advisable. Thus, LD<sub>50</sub> of the ethanolic extract of *A. squamosa* leaves  $> 5,000$  mg/kg bw, according to Hodge and Sterner method, the extract were practically non-toxic.

**Table 5.** Relative Organ Weight

Organ	Relative organ weight $\pm$ SD				
	Control	2,000 mg/kg bw	P	5,000 mg/kg bw	P
Liver	5.190 $\pm$ 0.944	5.763 $\pm$ 0.061	0.602	5.003 $\pm$ 0.759	0.943
Right kidney	0.600 $\pm$ 0.700	0.570 $\pm$ 0.021	0.706	0.563 $\pm$ 0.021	0.603
Left kidney	0.577 $\pm$ 0.136	0.593 $\pm$ 0.047	0.968	0.557 $\pm$ 0.021	0.954

p = significance; SD = deviation standard

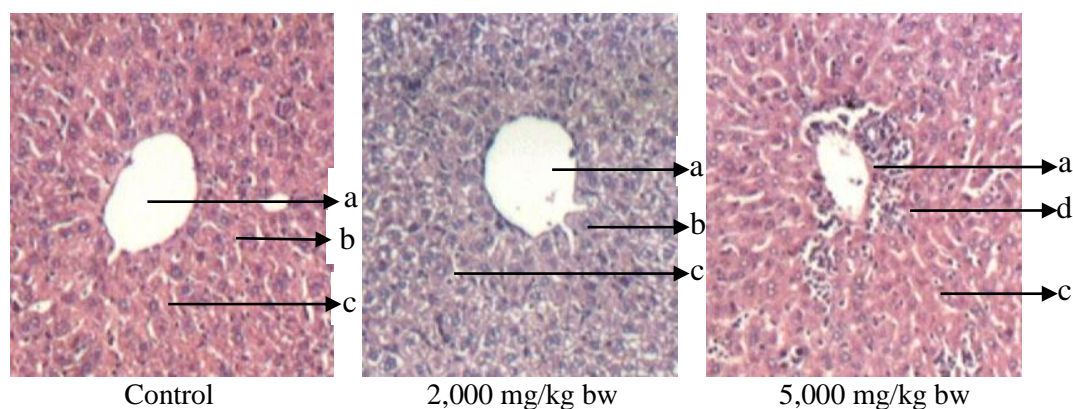
As shown in Table 5, the calculated relative weights of the control group and treated animal groups varied from one organ to another, but no significant differences ( $p > 0.05$ ) were noted in the relative weights of organs. The liver and kidneys of the control group were quite similar to those of the treated group with doses of 2,000 and 5,000 mg/kgbw with significance level of higher than 0.05. However, there was no correlation between the relative weights of the organ and the doses of the extract of *A. squamosa* leaves administered.

### 3.3. Gross Pathologic Observations

The gross appearance of internal organs like (liver and kidney) of treated mice show normal texture, shape and color, that condition is not difference to the control group. Liver involved in the metabolism of nutrients and most of the drugs and toxicants. Kidneys are the organs that excrete urine and other compounds, including toxicants. As a result, a kidney has a high volume of blood flow, concentrating filtrate of toxicants, through tubular cells and activates specific toxicant. Therefore, kidney is the main target of the toxic effect of any compound [8].

### 3.4. Histopathological Study

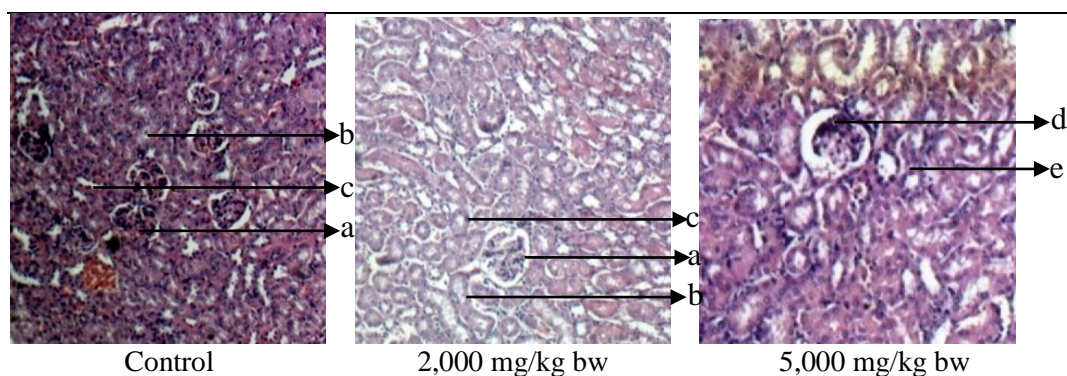
The results of liver histopathology can be seen in Figure. 1.



**Figure 1.** Histopathological study in liver  
a.normal central vein; b. normal hepatocytes; c. normal sinusoidal spaces; d. necrosis hepatocytes

As shown in the Fig. 1, the liver sections of control animal are showing the normal hepatic cells with well-preserved cytoplasm, prominent nucleus and central vein. Mice orally treated with the ethanolic extract of *A. squamosa* leaves dose of 2,000 mg/kg bw also showed a normal architecture of liver tissue but at dose of 5,000 mg/kg bw showed little abnormalities. There were cytoplasmic vacuolations (hydropic degenerations) in the hepatocytes located towards the periphery of the hepatic lobules around the central veins and necrosis hepatocytes.

The results of kidney histopathology can be seen in Figure. 2.



**Figure 2.** Histopathological study in kidney

a. normal glomerular; b. normal proximal tubule; c. normal distal tubule;  
d. glomerular atrophy; e. tubular dilation

The histopathological study in a kidney with dose of 2000 mg/kg bw of mice as shown in the Fig. 2 compared to the control group showed a normal architecture. At a dose of 5,000 mg/kg bw showed glomerular atrophy and dilation of some renal tubules. Glomerular atrophy present in mice treated with high dose of ethanolic extract of *A. squamosa* leaves may be due to slow circulation or tissue hypoxia [9].

#### 4. Conclusion

In conclusion, the ethanolic extract of *A. squamosa* leaves with doses of 2000 and 5,000 mg/kg bw were non toxic. In doses of 5,000 mg/kg bw caused change in the liver and kidney tissue, there were hydropic degeneration, necrosis hepatocyte and also glomerular atrophy and tubular dilatation, but there was no mortality was observed, so that LD<sub>50</sub> ethanolic extract of *A. squamosa* leaves was estimated >5,000 mg/kg bw and the extract are practically non-toxic.

#### Acknowledgment

The authors thanks to the technical support provided by the staffs of Laboratory of Pharmacology and Toxicology, Department of Pharmacology, Faculty of Pharmacy, University of Sumatera Utara.

#### REFERENCES

- [1] L. Handayani, H. Suparto, A. Suprpto, *Traditional system of medicine in Indonesia. Traditional Medicine in Asia*, p 47. 2001
- [2] R. K. Gupta, A. N. Kesari, P. S. Murthy, R. Chandra, V. Tandon, and G. Watal, "Hypoglycemic and antidiabetic effect of ethanolic extract of leaves of *Annona squamosa* L. in experimental animals," *Journal of Ethnopharmacology*, vol. 99, no. 1, pp. 75–81, May 2005.
- [3] G. A. El-Chaghaby, A. F. Ahmad, and E. S. Ramis, "Evaluation of the antioxidant and antibacterial properties of various solvents extracts of *Annona squamosa* L. leaves," *Arabian Journal of Chemistry*, vol. 7, no. 2, pp. 227–233, Apr. 2014.
- [4] D.S. Raj, J.J. Vennila, C. Aiyavu, K. Panneerselvam, "The hepatoprotective effect of alcoholic extract of *Annona squamosa* leaves on experimentally induced liver injury in Swiss albino mice". *Int J Int Bio.*;5(3):162-6. 2009
- [5] A. Sharma, T. Chand, M. Khardiya, K.C. Yadav, R. Mangal, A.K. Sharma, "Antidiabetic and antihyperlipidemic activity of *Annona squamosa* fruit peel in streptozotocin induced

- 
- diabetic rats”, *International journal of toxicological and pharmacological research*. Vol. 5, no.1, pp. 15-21, 2013.
- [6] R.Vivek, R. Thangam, K. Muthuchelian,P. Gunasekaran, K. Kaveri, S. Kannan, “Green biosynthesis of silver nanoparticles from *Annona squamosa* leaf extract and its in vitro cytotoxic effect on MCF-7 cells”, *Process Biochemistry*, vol.1, no. 47(12), pp. 2405-10, Dec. 2012
- [7] Organization for Economic Co-operation and Development Environment Directorate, *OECD environmental health and safety publications: Series on testing and assessment. Environment Directorate*, OECD, 2000.
- [8] L.C Junqueira, Carneiro J. *Basic histology: text and atlas*. McGraw-Hill Professional; 2005.
- [9] M.S.S. Al-Tameemi, T.A.A. Thekra, R.A. Hanan, M.N. Enas,S.A. Shuaa, S.G. Gamal, A.M. Awatif,A.N. Ban, “Studies on Acute Toxicity (LD50) and Histopathological Effects of Methanolic and Aqueous *Conocarpuslancifolius* Extracts in Mice”. *International Journal of Pharmacy and Pharmaceutical Research*, vol. 7, no.4, pp. 243-253. 2016