

Hepatoprotective Activity of *Curcuma mangga* Extract on Paracetamol-Induced Male Mice

Yuandani *, Silvia Mardaliza, Marianne

Department of Pharmacology, Faculty of Pharmacy, Universitas Sumatera Utara, Medan 20155, Indonesia

Abstract. This study was carried out to investigate the protective effect of ethanol extract of *Curcuma mangga* rhizomes on paracetamol-induced hepatotoxicity. High dose of paracetamol (1.35g/kg bw) was used to induce hepatic necrosis of mice liver. The male mice received ethanol extract of *C. mangga* rhizomes (100, 200 and 400 mg/kg BW) for 7 days. The hepatoprotective activity of extract was compared to normal, positive (curcuma) and negative control. The liver function was evaluated by measuring the biochemistry parameters which include alanine aminotransferase (ALT) and aspartate aminotransferase (AST). In addition, histopathological study on hepatic tissue section was also carried out. The *C. mangga* extract displayed hepatoprotective effect except at dose of 100 mg/kg bw. The increasing of serum levels of AST and ALT were inhibited after treatment with ethanol extract at doses of 200 and 400 mg/kg bw which was comparable with normal and Curcuma[®] as positive control ($p > 0.05$). In addition, histological assessment of hepatic tissue demonstrated no liver damage, specially at dose of 400 mg/kg BW. The result indicate that ethanol extract of *C. mangga* rhizomes has hepatoprotective effect, especially at doses of 200 and 400 mg/kg bw .

Keywords: *C. mangga*, rhizomes, biochemistry parameters, histopathology

Abstrak. Penelitian ini dilakukan bertujuan untuk mengetahui efek perlindungan dari ekstrak etanol rimpang *Curcuma mangga* pada hepatotoksitas yang diinduksi parasetamol. Parasetamol dosis tinggi (1,35 g/kgbb) digunakan untuk menginduksi nekrosis hati pada tikus. Tikus jantan diberikan ekstrak etanol rimpang *C. mangga* (100, 200 dan 400 mg/kg bb) selama 7 hari. Aktivitas hepatoprotektif ekstrak dibandingkan dengan kontrol normal, positif (*curcuma*) dan negatif. Fungsi hati dievaluasi dengan mengukur parameter biokimia yaitu alanine aminotransferase (ALT) dan aspartate aminotransferase (AST). Selain itu, pemeriksaan histopatologis pada bagian jaringan hati juga dilakukan. Ekstrak *C. mangga* menunjukkan efek hepatoprotektif kecuali pada dosis 100 mg/kg bb. Peningkatan kadar serum AST dan ALT dihambat setelah pemberian ekstrak etanol pada dosis 200 dan 400 mg/kgbb yang dibandingkan dengan kontrol normal dan Curcuma[®] sebagai kontrol positif ($p > 0,05$). Selain itu, penilaian histologis jaringan hati menunjukkan tidak ada kerusakan hati, khususnya pada dosis 400 mg/kg bb. Hasil penelitian menunjukkan bahwa ekstrak etanol rimpang *C. mangga* memiliki efek hepatoprotektif, terutama pada dosis 200 dan 400 mg/kg bb.

Kata kunci: *C. mangga*, rimpang, parameter biokimia, histopatologi

Received 30 August 2018 | Revised 2 October 2018 | Accepted 26 November 2018

*Corresponding author at: Universitas Sumatera Utara, Medan, Indonesia

E-mail address: yuandani@usu.ac.id

1. Introduction

Nowadays, utilization of hepatoprotective drugs to treat various hepatic diseases has increased. Hepatoprotective agents are normally used in patients with elevated biochemistry parameters such as alanin aminotransferase (ALT) and aspartat aminotranferase (AST) [1]. There are some conditions which may arise the AST and ALT levels, which include liver inflammation or drug-induced liver disease. Several drugs are widely known to induce liver damage. These include paracetamol, isoniazid, rifampin, metothrexate and phenitoin [2]. Paracetamol (acetaminophen) is considered un toxic at therapeutic doses and short term use. Paracetamol undergo metabolism by the enzymes cytochrome P450 to toxic metabolit, known as N-acetyl-p-benzoquinone imine (NAPQI) [3].

Hepatoprotective drugs have been studied for its possibility to treat virus-induced chronic hepatitis [4]. Discovery and development of hepatoprotective drugs has gained momentum in recent years. Medicinal plants preserve a source of hepatoprotective drugs [1].

Curcuma mangga rhizome was found to be rich in various bioactive compounds. These include secondary metabolite compounds with medicinal importance such as curcumin, β -sitosterol, bisdemethoxycurcumin and demethoxycurcumin [5-6]. This plant has long been used in traditional medicine for the treatment of various diseases such as fever, stomach disorders and cancer [6]. Previous study has showed the immunomodulatory properties of *C. mangga* [7]. The anticancer, anti-inflammatory, antifungal and nitric oxide inhibitory activities of *C. mangga* have also been reported [8-11]. Safety assessment which revealed that it was un toxic in show short-term treatment has emphasized to evaluate its hepatoprotective activity [12]. The current study was carried out to evaluate the effects of *C. mangga* extract on its ability to prevent hepatic necrosis which induced by high dose of paracetamol.

2. Materials and Methods

2.1. Chemicals and reagents

There were several chemicals used in this study, natrium carboxylmethlcellulose (Na CMC), ethanol (SmartLab, Indonesia) (Sigma, USA), and Curcuma[®] (Soho, Indonesia). A light microscope (Boeco, Germany) and rotary evaporator (Heidolph, Germany) were also used in this study.

2.2. Plant materials

The *C. mangga* rhizomes were obtained from Deli Serdang, Indonesia. The plant was identified by Herbarium Medanese (MEDA) Universitas Sumatera Utara, Indonesia.

2.3. Extraction procedure

The extract was prepared by maceration method. Briefly, the *C. mangga* rhizomes materials were cut, dried and ground. Then 500 g of sample was soaked in ethanol at ratio 1:10, then filtered after 3 days. Again, the residue was soaked and filtered after another 3 days. Thereafter, the combined filtrates were evaporated to remove the solvent and to obtain ethanol extract of *C. mangga*.

2.4. Experimental Procedure

The protective effect on liver was evaluated followed a modified previous method [13]. The mice received *C. mangga* extract at doses of 100, 200 and 400 mg/kg bw for 7 days by oral route. Curcuma[®] (54 mg/kg bw) was used as positive control. The negative control and normal group were treated with Na CMC 0.5% as vehicle. On day 7, except normal group, all mice were induced by high dose of paracetamol (1,35g/kg bw). After 24 hours, the mice were sacrificed and blood were collected for biochemical parameters examination. Histological assesment was performed on hepatic tissue section. The use of mice was approved by the Animal Research Ethics Committees of Universitas Sumatera Utara (approval number 098/KEPH-FMIPA/2017).

2.5. Biochemical Parameters Evaluation

The blood were centrifuged for 20 min at 3000 rpm. Thereafter, the serum was separated to determine the levels of alanin aminotransferase (ALT) and aspartate aminotranferase (AST).

2.6. Histological Assesment

Microscopic examination on tissue section was conducted by slicing with a microtome after the liver has been embedded in paraffin. Observation was performed using a light microscope.

2.7. Statistical analysis

The data were analyzed using SPSS 17.0 using ANOVA a one-way ANOVA. Then, followed by Tukey post hoc test. The different significance was ANOVA at $P < 0.05$.

3. Results And Discussion

3.1. Biochemical Parameters

The *C. mangga* extract at dose of 100 mg/kg BW still showed comparable ALT and AST levels to negative control ($P > 0.05$) as shown in Table 1. The extract started to prevent paracetamol-induced hepatic necrosis at dose of 200 and 400 mg/kg bw which indicated by normal values of ALT and AST when compared to negative control ($P < 0.05$). The high dose of acetaminophen induced liver damage due to the decreasing store of Glutathione S-transferase pi 1 (GSTP1). This condition causes a reactive metabolite NAPQI begins to react to hepatocytes and induced hepatic necrosis [2]. The extract of *C. mangga* was

able to prevent induced liver damage by preventing increase level of ALT and AST after treatment with large dose of paracetamol. The levels of ALT and AST are normally used to monitor liver function because they are released by hepatic tissue damage [14]. The *C. mangga* extract at dose of 200 and 400 mg/kg bw demonstrated comparable hepatoprotective activity with normal and positive control ($P > 0.05$).

Table 1. Effect of extract on ALT and AST levels after treatment with paracetamol (Mean \pm SD)

No.	Groups	ALT (IU/L)	AST (IU/L)
1.	Normal (Na-CMC 0,5% without paracetamol)	111.75 \pm 11.84	245.00 \pm 30.04
2.	Negative control (Na-CMC 0,5% with paracetamol)	697.75 \pm 11.14*	813.50 \pm 41.58*
3.	Positive control (Curcuma 58 mg/kg bw)	171.75 \pm 76.03 ^a	288.75 \pm 59.67 ^a
4.	<i>C. mangga</i> extract 100 mg/kg bw	675.25 \pm 256.51 ^{b,*}	785.25 \pm 44.39 ^{b,*}
5.	<i>C. mangga</i> extract 200 mg/kg bw	212.25 \pm 10.53 ^{a,*}	306.43 \pm 12.19 ^a
6.	<i>C. mangga</i> extract 400 mg/kg bw	187.75 \pm 11.21 ^{a,*}	266.18 \pm 10.12 ^a

a = significantly different with negative control ($p < 0.05$)

b = significantly different with positive control ($p < 0.05$)

* = significantly different with normal ($p < 0.05$)

3.2. Histological Assessment

Figure 1 shows necrotic cells after treatment by large dose of paracetamol. Microscopic examination on hepatic tissue showed no hepatic necrosis after treatment by *C. mangga* extract at dose of 200 and 400 mg/kg bw. The result was in agreement with the biochemistry examinations, the *C. mangga* extract prevented the necrotic hepatocytes in liver. The curcuminoid content which include curcumin, demethoxycurcumin and bisdemethoxycurcumin in *C. mangga* rhizomes might play important role in inhibiting hepatic necrosis induced by paracetamol [5].

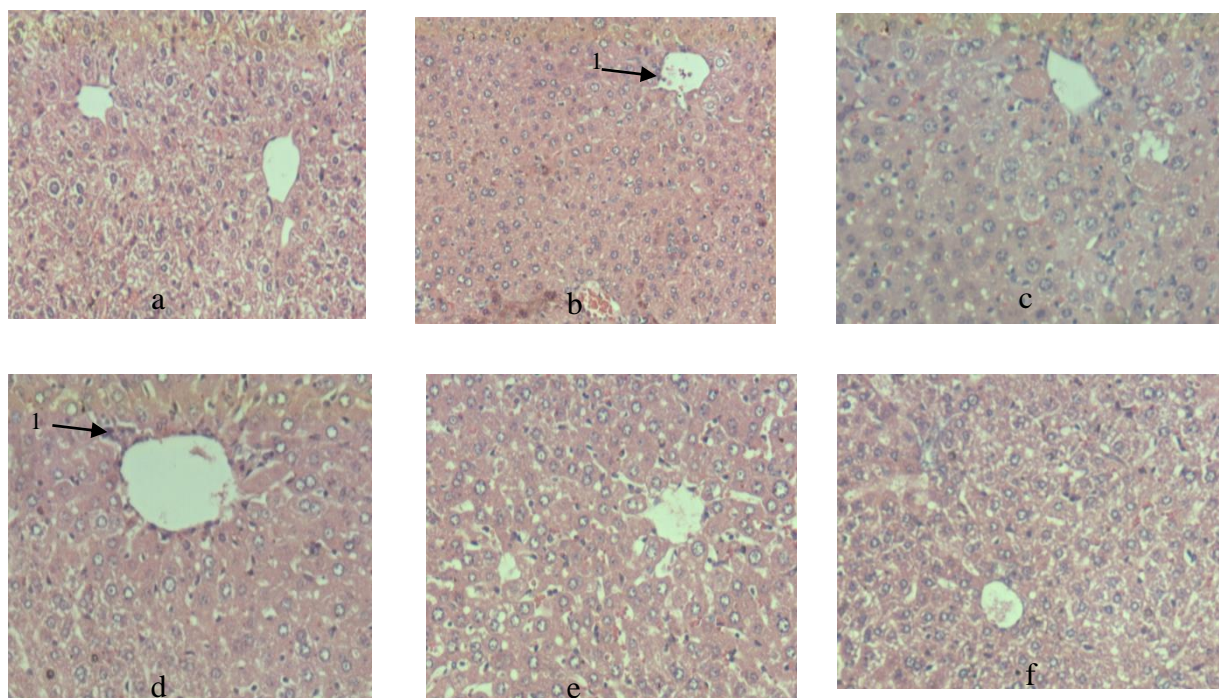


Figure.1. Microscopic examination (10×10). (a) Liver of normal control rat; (b) liver of negative control rat; (c) Liver of positive control rat; (d) Liver after treatment with *C. mangga* extract at 100 mg/kg; (e) Liver after treatment with *C. mangga* extract at 200 mg/kg; (f) Liver after treatment with *C. mangga* extract at 400 mg/kg; (1) necrotic hepatocyte

4. Conclusion

The ethanol extract of *C. mangga* rhizomes displayed hepatoprotective activity at dose of 200 and 400 mg/kg bw. The extract prevented increase in serum ALT and AST after treatment with high dose of paracetamol. The result was supported by no necrotic hepatocyte observed within the liver after treatment by extract. However, further studies are necessary to elucidate the hepatoprotective mechanism of *C. mangga* rhizomes.

ACKNOWLEDGEMENT

Nil

REFERENCES

- [1] S.D. Roy, S. Das, D. Shil, and K.N. Dutaa, "Herbal hepatoprotective agents: a review", *World J Pharm Res*, vol. vol.1, no. 2, pp. 87-99, 2012.
- [2] J. T. DiPiro, R. L. Talbert, G. C. Yee, G. R. Matzke, B. G. Wells, L. M. Posey, D. S. Streetman, and D.-A. D. Streetman, "Book Review: Pharmacotherapy: A Pathophysiologic Approach, 7th Edition," *Annals of Pharmacotherapy*, vol. 43, no. 2, pp. 395–395, Feb. 2009.
- [3] R. B. Pingili, A. K. Pawar, and S. R. Challa, "Systemic exposure of Paracetamol (acetaminophen) was enhanced by quercetin and chrysin co-administration in Wistar rats and in vitromodel: risk of liver toxicity," *Drug Development and Industrial Pharmacy*, vol. 41, no. 11, pp. 1793–1800, Feb. 2015.
- [4] T. Okamoto, K. Kajino, and O. Hino, "Hepatoprotective Drugs for the Treatment of Virus-Induced Chronic Hepatitis: From Hypercarcinogenic State to Hypocarcinogenic State.," *The Japanese Journal of Pharmacology*, vol. 87, no. 3, pp. 177–180, 2001
- [5] S. N. A. Malek, G. S. Lee, S. L. Hong, H. Yaacob, N. A. Wahab, J.-F. Faizal Weber, and S. A. A. Shah, "Phytochemical and Cytotoxic Investigations of Curcuma mangga Rhizomes," *Molecules*, vol. 16, no. 6, pp. 4539–4548, May 2011.
- [6] F. Abas, N. H. Lajis, K. Shaari, D. A. Israf, J. Stanslas, U. K. Yusuf, and S. M. Raof, "A Labdane Diterpene Glucoside from the Rhizomes of Curcumamangga," *Journal of Natural Products*, vol. 68, no. 7, pp. 1090–1093, Jul. 2005.
- [7] Y. Yuandani and E. Suwarso, "Immunomodulatory effects of ethanol extract of curcuma mangga rhizomes in mice," *Asian Journal of Pharmaceutical and Clinical Research*, vol. 10, no. 9, p. 148, Sep. 2017.
- [8] P. Ruangsang, S. Tewtrakul, and W. Reanmongkol, "Evaluation of the analgesic and anti-inflammatory activities of Curcuma mangga Val and Zipp rhizomes," *Journal of Natural Medicines*, vol. 64, no. 1, pp. 36–41, Oct. 2009.
- [9] R. Tjandrawinata, A. H. Karsono, and O. M. Tandrasasmita, "Molecular effects of bioactive fraction of Curcuma mangga (DLBS4847) as a downregulator of 5 α -reductase activity pathways in prostatic epithelial cells," *Cancer Management and Research*, p. 267, Jun. 2014.
- [10] F. Abas, N. H. Lajis, D. A. Israf, S. Khozirah, and Y. Umi Kalsom, "Antioxidant and nitric oxide inhibition activities of selected Malay traditional vegetables," *Food Chemistry*, vol. 95, no. 4, pp. 566–573, Apr. 2006.
- [11] I. bin Jantan, M. S. M. Yassin, C. B. Chin, L. L. Chen, and N. L. Sim, "Antifungal Activity of the Essential Oils of Nine Zingiberaceae Species," *Pharmaceutical Biology*, vol. 41, no. 5, pp. 392–397, Jan. 2003.
- [12] Yuandani and E. Suwarso, "Acute Toxicity Evaluation Of Ethanol Extract Of Curcuma Mangga Rhizome," *Asian Journal of Pharmaceutical and Clinical Research*, vol. 10, no. 1, p. 383, Jan. 2016.
- [13] M. T. Olaleye, A. E. Amobonye, K. Komolafe, and A. C. Akinmoladun, "Protective effects of Parinari curatellifolia flavonoids against acetaminophen-induced hepatic necrosis in rats," *Saudi Journal of Biological Sciences*, vol. 21, no. 5, pp. 486–492, Nov. 2014.
- [14] L.K. Yin, and K.S. Tong, "Elevated alt and ast in an asymptomatic person What the primary care doctor should do?" *Malays Fam Physician*, vol. 4 no.2.2009