

Brown Tumor of Lower Right Limb in Patients With Primary Hyperparathyroidism: A Case Report

Muhammad Iqbal¹, Santi Syafri²

^{1,2}Department of Internal Medicine, Faculty of Medicine, University of Sumatera Utara, Medan, North Sumatera, Indonesia

Abstract.

Background. Brown tumor of Hyperparathyroidism is a metabolic disorder that can affect the entire skeleton and reactive process due to bone resorption caused by primary or secondary hyperparathyroidism (HPT). Brown tumors can occur as solitary or multiple lesions in any bone, most often in the pelvis, ribs, clavicle, mandibula, and extremities. Here, we report the Brown tumor in the lower right limb in patients with primary HPT, and the literature is reviewed.

Case presentation. Patients was women 30 years old had married and come with main complains of difficulty walking. This condition has been experienced by patients since diagnosis with lumb of tibia last 8 months and caused pain from hip to lower leg. On laboratory results, it showed elevated PTH 1.249 (normal 15-65) pg/dL, elevated phosphatase alkali 1156 (normal 40-150) u/dL, elevated Ca 10,8 (n:8,6 -10,3) mg/dL, phosphor 2,1 (3-4,5) mg/dL. Histology examination of tibia lump was a benign lesion of bone (Brown Tumor). Ultrasonography transabdominal result revealed kidney stones with bilateral renal pelvis dilation, nephrolithiasis non-obstructive was found with size 1 cm & left kidney cyst with size 0.6 cm. On Neck USG showed giant cyst lesion on parathyroid glands. Radiologist pelvic examination results showed bone metastasis disease. Head CT Scan examination concluded as suspect metastatic bone. Body bone scans examination showed pathological bone metastatic process.

Conclusion. Brown tumor in right lower limb caused by primary HPT

Keyword: hyperparathyroidism, brain tumor, bone metastasis, tibia tumor

Abstrak.

Latar belakang. Brown tumor dari hiperparathyroidism itu adalah gangguan metabolisme yang mempengaruhi seluruh rangka dan proses bersifat reaktif terhadap resorpsi tulang yang disebabkan oleh hiperparathyroidism primer atau sekunder (HPT). Brown tumor

*Corresponding author at: Department of Internal Medicine, Faculty of Medicine, University of Sumatera Utara, Medan, North Sumatera, Indonesia

E-mail address: benzene.abe@gmail.com

terjadi sebagai lesi soliter atau ganda di tulang apa pun, paling sering di panggul, tulang rusuk, klavikula, mandibula, dan ekstremitas. Di sini, kami melaporkan Brown tumor pada tungkai bawah kanan pada pasien dengan HPT primer dan ditinjau dari tinjau.

Presentasi kasus. Seorang wanita dengan RBP, usia 30 tahun, menikah dan mengeluh kesulitan berjalan. Kondisi ini telah dialami oleh pasien karena nyeri pada anggota tubuh kanan bawah dan pinggul bawah, Ada benjolan di tibia sejak 8 bulan yang lalu. Hasil laboratorium yang relevan: darah rutin normal. PTH 1.249 (normal 15-65) pg/dL, fosfatase alkali tinggi 1156 (normal 40-150) u/dL, tinggi Ca 10,8 (n:8,6 -10,3) mg/d, fospor 2,1 (3 – 4,5) mg/dL. Pemeriksaan histopatologi benjolan di tibia menunjukkan lesi jinak tulang (Brown Tumor). USG abdomen menunjukkan batu ginjal dengan pelebaran bilateral pelvis ginjal dan nefrolithiasis kanan non obstruktif ukuran 1 cm & kista ginjal kiri ukuran 0,6 cm. Pada USG leher ditemukan lesi kista paratiroid, tiroid ukuran normal, ekogenitas parenkim homogen, tidak ada lesi fokus dan tidak ada pembesaran getah bening. CT Scan kepala menunjukkan sangkaan metastatik pada tulang, Pada pemeriksaan Bone scan ditemukan gambar patologis proses metastatik tulang dan pada pemeriksaan radiologi panggul ditemukan penyakit metastasis tulang.

Kesimpulan. Brown tumor pada tungkai kanan bawah disebabkan HPT yang primer

Kata kunci: hipertiroid, tumor otak, metastasis tulang, tumor tibia.

Received 05 September 2021 | Revised 30 November 2021 | Accepted 30 November 2021

1 Introduction

Brown tumor, an uncommon focal giant cell lesion, is a nonneoplastic and reactive process due to bone resorption and localized osseous lesion caused by primary or secondary hyperparathyroidism (HPT).[1] Brown tumors can occur as solitary or multiple lesions in any bone, most often in the pelvis, ribs, clavicle, mandibula, and extremities. [1]

Here, we report the Brown tumor in the lower right limb in patients with primary HPT and the literature is reviewed.

2 Case Illustration

Our patients was 30 years old, married woman came with complains of difficulty walking. This condition has been experienced by patients since 8 months ago due to pain in lower hip to right limb caused by lump of tibia. Shaking hands and palpitation was found. Patients never experienced any trauma. History of taking any drugs or exposure to chemical was denied. History of family with same disease not found. Nutritional status was normal with bogy weight 60 kg and body height 165 cm and calculated body mass index was 22.03 kg/m² (normoweight). General examination was done, patients was alert with respiratory rate 20 rpm, pulse rate 84 bpm, blood pressure 110/70 mmHg and temperature 36.7°C. On ECG examination found sinus rhythm. On laboratory results found elevated PTH 1.249 (normal 15-65) pg/dL, elevated phosphatase alkali

1156 (normal 40-150) u/dL, elevated Ca 10,8 (n:8,6 -10,3) mg/d, phosphor 2,1 (3 – 4,5) mg/dL. On Histopathology examination of tibia lump result concluded as benign lesion of bone (Brown Tumor). On Ultrasonography transabdominal results revealed kidney stones with bilateral renal pelvis dilation and right nephrolithiasis non-obstructive with size 1 cm & left kidney cyst with size 0.6 cm (fig. 1).

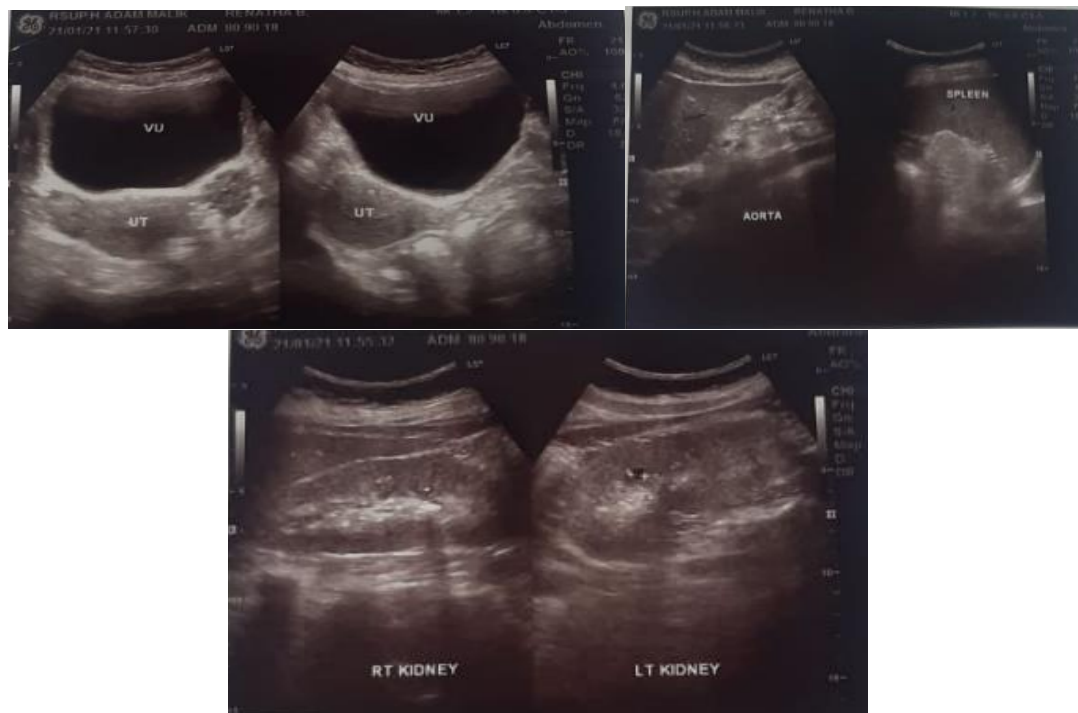

Figure 1 Transabdominal Ultrasonography results revealed kidney stones with bilateral renal pelvis dilation

On Neck ultrasonography results showed giant cyst lesion on parathyroid glands, normal size thyroid, homogeneous parenchymal echogenic without focal lesions and without lymph enlargement (fig. 2). On Head CT Scan examination found suspect metastatic bone (fig. 3),

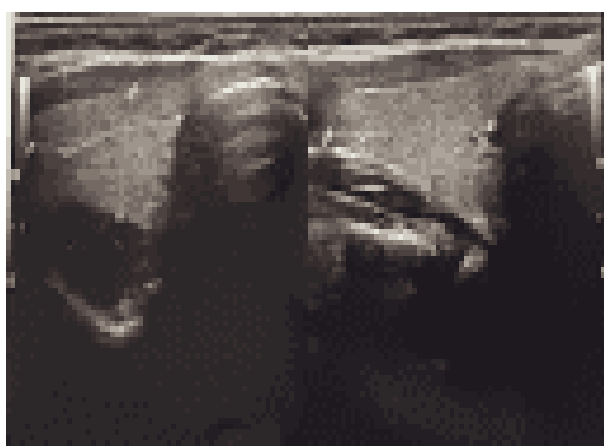

Figure 2 Neck ultrasonography results showed giant cyst lesion on parathyroid glands.

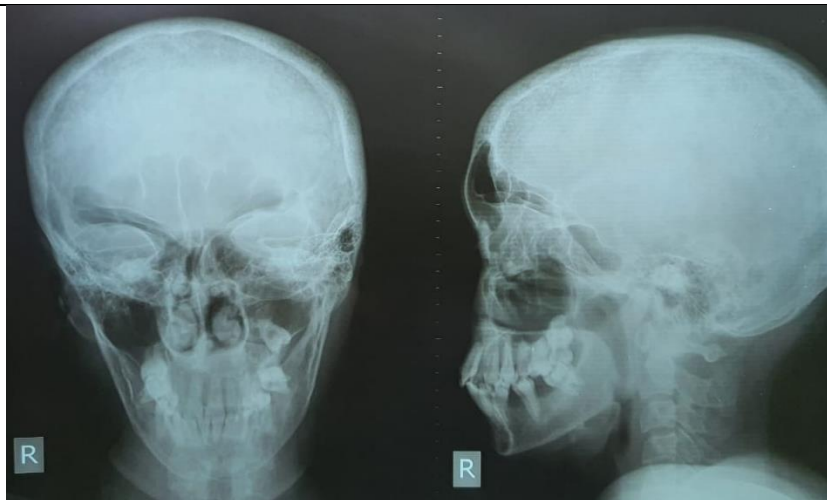

Figure 3 On Head CT Scan examination found suspect metastatic bone

On Body bone scans found pathological picture of bone metastatic process (fig. 4), X-ray pelvic found bone metastasis disease (fig. 5). On Lower Limb X-ray found lump of tibia. (Figure 6)




Figure 4 Body bone scans found pathological picture of bone metastatic process

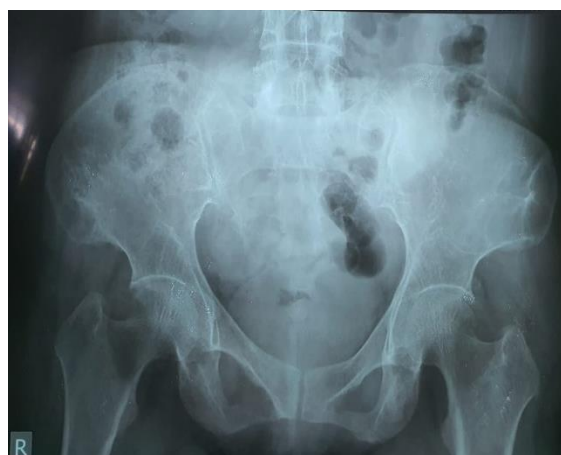

Figure 5 X-ray pelvic found bone metastasis disease

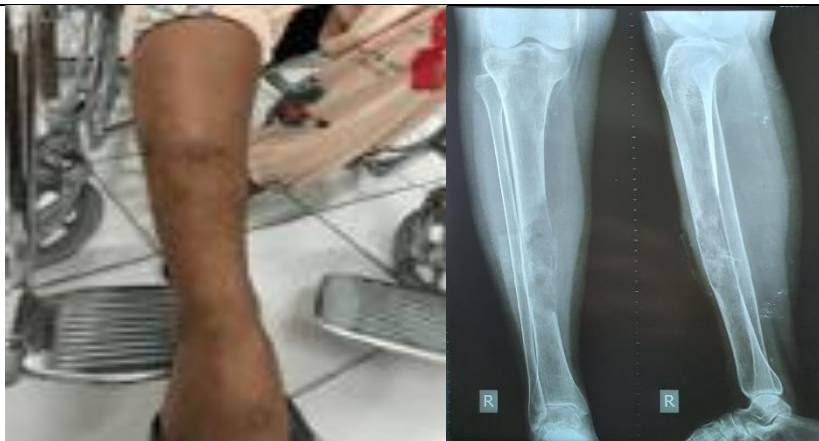

Figure 6 Lower Limb X-ray found lump of tibia

Patient then diagnosed with Brown tumor in right lower limb caused by primary HPT and planned for surgery management.

3 Discussion

The Brown Tumour generally shows multiple occurrences, although it can also occur as a single one. When present in the mandibular bone, it usually appears at the hard blade.[2] Besides, one could observe bone trabeculae neoformed with osteoblasts' tumefactions on its edges. Blood tests indicate the increased levels of calcium and alkaline phosphates, as well as the reduction in the level of phosphorus, is useful for finding the correct diagnosis. [1] The Brown Tumor does not demand specific treatment in most cases because the correction of hyperparathyroidism leads to the lesion disappearance event. However, it can cause pathological fractures and bone marrow compression even when it involves the spine. When it reaches the face can cause breathing difficulties and facial deformities. In such cases, it is recommended that the patient undergoes surgical treatment. [3]

Brown tumors are focal bone lesions, caused by increased osteoclastic activity and fibroblastic proliferation, encountered in patients with uncontrolled hyperparathyroidism (HPT). They can be located in any part of the skeleton, but are most frequently encountered in the ribs, clavicles, extremities, and pelvic girdle. Clinically significant lesions in the cranio-facial bones are rare. [5] Clinically significant lesions in the diaphysis of the tibia are rare and pose a diagnostic challenge to the clinician.[7]

This disorder, called brown tumour, has its determinant a metabolic bone disarray caused by the excess production of parathyroid hormone, which is produced by the four parathyroid glands located posterior to the thyroid gland, which are responsible for the control of phosphorus (P), calcium (Ca) and vitamin D; The level of calcium present in the blood is considered a triggering factor of the disorder by the release and production of this hormone. Shetty “the hyperparathyroidism HPT is a disease in which there may be a complex, of biochemical anatomic

and clinical abnormalities. Brown Tumor has its histopathological complexity described as multiple adenomas, numerous osteoclastic cells, of cystic format, and separated by a highly vascularized tissue which will confer the lesion a dark red or brownish coloration which characterizes its nickname. Some of the signs and symptoms observed in this disorder are fatigue, nausea, weakness, anorexia, excessive thirst, polyuria, constipation, pain, swelling and frequent urination. In severe cases, may present kidney stones, loss of bone mass and fractures, mental confusion and consequent depression. The parathyroid glands were increased in cervical ecography. The findings of hyperparathyroidism were confirmed together with other exams to the diagnosis of Brown Tumour of Hyperparathyroidism.[4]

Histological characteristics of brown tumor demonstrate highly vascular connective tissue with diffusely distributed multinucleated giant cells, and areas of hemorrhage and hemosiderin deposits [6]. Skeletal demineralization, resulting from elevated plasma calcium, leads to multinucleated giant cells or osteoclasts replacing bone. [6] Diagnosis is best established by evaluation of serum levels of calcium and phosphorous, alkaline phosphatase and parathyroid hormone, or by finding an increased amount of urinary calcium. There is no pathognomonic histopathologic features for this condition. The osseous trabeculae can be resorbed, proliferating fibroblastic connective tissue is usually scattered with benign osteoclast-like giant cells.[12]

Initial treatment involves correction of hyperparathyroidism, which usually leads to tumor regression. Tumor preventive treatment objectives for patients with chronic renal failure include normalizing blood levels of calcium and phosphate. [6] Treatment of hypocalcemia is based on oral and intravenous calcium replacement. Reported daily requirements of calcium in patients with severe hypocalcemia range from 6 to 16 g of elemental calcium per day.[8] Treatment of primary hyperparathyroidism often requires surgical resection of an adenoma, causing a sudden halt in bone turnover. Consequently, a marked depletion of serum circulating calcium, phosphate, and magnesium is seen due to bone remineralization.[9] The preferred calcium administration route depends on signs and symptoms severity, promptness of the onset of manifestations, and serum calcium levels.[10] Oral calcium supplementation could be reasonably used in patients with mild symptoms and serum calcium concentrations greater than 7.5 mg/dL intravenous treatment is required for patients with calcium below this level or prolonged QTc interval on electrocardiogram and may be necessary for those cases who are currently unable to swallow or absorb oral calcium.[10] Intravenous calcium gluconate is preferred over calcium chloride due to its lower association with local irritation. For acute hypocalcemia management, one or two 10mL ampoules of 10% calcium gluconate (10 mL of a 10% solution = 93 mg elemental Ca or 1 ampule) should be diluted in 50– 100 mL of 5% dextrose or saline to infuse it over 10 minutes.[11]

The main treatment of brown tumor is surgical removal of hyperfunctioning parathyroid gland. [12] The prophylactic internal fixation for large bone lesions should be done to prevent spontaneous fracture. Significant clinical improvement has been found among

patients with bone defects treated with tumor curettage and stabilization of the long bone with less invasive stabilization system. It must be supplemented with calcium and vitamin D.[7]

4 Conclusion

In conclusion, reported a rare case with diagnose Brown tumor of lower right limb with primary hyperparathyroidism and prepared for surgery management.

REFERENCES

- [1] Fargen KM, Lin CS, Jeung JA, et al., "Vertebral brown tumor causing neurologic compromise.," *World Neurosurg* , vol;79:208, 2013. p: e1–6.
- [2] Farias JG, Carneiro GGVS, Batista BA, Barreto-Neto LO, Moraes LC, et al., "Avaliação odontológica-cirúrgica do paciente renal crônico.," *Rev Cir Traumatol Buco-Maxilo-Facial*, vol. 8(1): 2008. pp. 9-14.
- [3] Yamashita U, Akiyama T, Mizusawa N, Yoshimoto K, Goto M, "A case of hyperparathyroidism-jaw tumour syndrome found in the treatment of an ossifying fibroma in the maxillary bone.," *Int J Oral Maxillo fac Surg*, vol. 36(4): 2007. pp. 365-369.
- [4] Marcelo P, Gustavo B, Roberto S, Fábio R, Jonathan P, Hugo M, Célia A. Brown tumour revealed: A literature review with a case study. *Biomed J Sci & Tech Res* 1(7)-2017. BJSTR. MS.ID.000587. DOI : 10.26717/BJSTR.2017.01.000587.
- [5] Can O; Boynuegri B; Gokce AM; Ozdemir E; Ferhatoglu F; Canbakan M; et al. Brown Tumors: A Case Report and Review of the Literature. *Case Rep Nephrol Dial* 2016;6:46–52.
- [6] Mascarenhas LS; Marchionni AMT; Reboucas DS; Neri JSV; Maedrado ARAP. Brown tumor as a result of secondary hyperparathyroidism in chronic renal disease. *J Oral Diag* [online] 2016; 01:e20160021.
- [7] Vaishya R, Agarwal A, Vijay V, et al. A Brown Tumor of Tibial Diaphysis Masquerading as Malignancy . *Cureus*. 2017; 9(6): e1319. DOI 10.7759/cureus.1319
- [8] M. Corsello, R. M. Paragliola, P. Locantore et al., "Post-surgery severe hypocalcemia in primary hyperparathyroidism preoperatively treated with zoledronic acid," *Hormones*, , vol. 9, no. 4. 2010. pp. 338–342.
- [9] A. R. Brasier and S. R. Nussbaum, , "Hungry bone syndrome: clinical and biochemical predictors of its occurrence after parathyroid surgery," *The American Journal of Medicine*, , vol. 84, no. 4. 1988. pp. 654–660.
- [10] J. Fong and A. Khan, , "Hypocalcemia: updates in diagnosis and management for primary care," *Canadian Family Physician Médecin de Famille Canadien*, , vol. 58, no. 2. 2012. pp. 158–162.
- [11] M. S. Rathi, R. Ajjan, and S. M. Orme, "A case of parathyroid carcinoma with severe hungry bone syndrome and review of literature," *Experimental and Clinical Endocrinology & Diabetes*, vol. 116, no. 8. 2008. pp. 487–490.

-
- [12] Kamal AF; Isdianto PA; Abdullah A; Kodrat E. Brown tumors of hyperparathyroidism misdiagnosed as multifocal Giant Cell Tumors of bone: A case report. *Human Pathology: Case Reports* 21 (2020) 200385