

Research Article

Subacute Toxicity of Yellow Flower Extract (*Cananga odorata*) on the Histopathology of White Rat Heart (*Rattus norvegicus*)

Suresh Mani¹, Ratna Akbari Ganie², Dina Keumala Sari^{*3}, Liza Meutia Sari⁴, Meike Rachmawati⁵, Noorzaid Muhamad⁶

¹Department of Physiotherapy, School of Applied Medical Sciences, Lovely Profesional University, Punjab, 144402, India

²Department of Clinical Pathology, Faculty of Medicine, Universitas Sumatera Utara, Medan, 20155, Indonesia

³Department of Nutrition, Faculty of Medicine, Universitas Sumatera Utara, Medan, 20155, Indonesia

⁴Department of Oral Medicine, Faculty of Dentistry, Universitas Syiah Kuala, Banda Aceh, 23111, Indonesia

⁵Department of Anatomical Pathology, Faculty of Medicine, Universitas Islam Bandung, Bandung, 40116, Indonesia

⁶Department of Integrative Physiology and Molecular Medicine, Faculty of Medicine, Royal College of Medicine, Universitas Kuala Lumpur, Perak, 30450, Malaysia

Abstract

Background: The inflammatory process is influenced by chemical mediators such as Nitric Oxide (NO), cytokines, and arachidonic acid metabolites. The therapeutic effect of herbal plants comes from phytochemicals with strong antioxidant activity. **Objective:** To examine the phytochemical content and anti-inflammatory effects of *Cananga odorata*. **Methods:** This was a two-stage study: in vitro and in vivo. Anti-inflammatory activity is related not only to antioxidant properties but also to suppression of nitric oxide and pro-inflammatory cytokines. This effect is being explored using various herbal plants. One such plant is *Cananga odorata* (ylang flower), a tropical plant with fragrant petals that grows easily. **Results:** The total phenol content was 1.06% w/w. Antioxidant activity measured using DPPH method showed an IC50 of 808.86 ppm, indicating weak antioxidant activity. In rats, the extract reduced blood glucose levels but had no effect on lipid profiles. Toxicity testing showed no toxic effects. Histological analysis showed no differences between cardiovascular disease model mice and standard-fed mice. **Conclusion:** The ethanol extract of *Cananga odorata* did not show toxicity in the heart histopathology of white rats.

Keywords: antioxidant, flower, inflammation, phytochemicals, rat, remembrance

Received: 05 May 2023 | Revised: 14 May 2023 | Accepted: 14 May 2023

1. Introduction

Ylang (*Cananga odorata*) is the name for a type of flower and the tree that produces it. There are two main groups of ylang cultivated, namely the *Cananga* group (Forma *marcophylla* Steeins) and Ylang-ylang (Forma *genuina* Steeins). *Cananga* has branches perpendicular to the stem while Ylang-ylang has drooping branches and smaller leaves. In addition, the *cananga* shrub (*Cananga odorata fruticosa*) is also known, which is widely grown as an ornamental plant in the yard. Ylang is a typical flora for India, Indonesia, and Malaysia especially in North Sumatera as folk medicine. It also has the potential to be studied, especially for herbal medicines with anti-inflammatory effects [1, 4].

Inflammation is a complex response of the host to injury that results in the release of leukocytes and extravasation of plasma proteins. Some of the diseases or sport injury associated with inflammation, some of

* Corresponding author at: Department of Nutrition, Faculty of Medicine, Universitas Sumatera Utara, Medan, 20155, Indonesia
E-mail address: dina@usu.ac.id

diseases such as cardiovascular disease, metabolic disorders, neurological disorders, rheumatoid arthritis, and pulmonary disease. Sports injury also produce inflammation reactions and pro-oxidant. The inflammatory process is influenced by chemical mediators such as nitric oxide (NO), cytokines, and arachidonic acid metabolites. Treatment of this inflammatory disorder usually uses non-steroidal anti-inflammatory drugs (NSAIDs) and corticosteroids for a long time. The mechanism of action of this synthetic drug is the inhibition of enzymes that produce arachidonic acid to inhibit the expression of cytokines. This synthetic drug has proven to be effective in treating symptoms of inflammation, but its therapeutic action can cause unwanted effects such as gastrointestinal damage [5].

Currently, herbal treatment techniques are preferred by the public because they generally do not cause side effects. The therapeutic effect of herbal plants comes from the content of phytochemicals that have strong antioxidant activity. Many previous studies have proven that anti-inflammatory activity is not only related to antioxidant activity but also its ability to suppress the production of nitric oxide and pro-inflammatory cytokines. This effect is still being developed using a variety of herbal plants. One of the plants whose effects have not been studied in the field of health-medicine is ylang flower [6, 9].

Cananga odorata (Annonaceae) or ylang flower plant is a tropical plant that has fragrant petals and thrives without requiring special care. Today ylang flower extract is produced in large quantities as ylang-ylang essential oil due to its freshness and fragrance. Its role in the perfume industry has grown rapidly, but information about the potential of ylang flower in medicine and dentistry has not been widely investigated [2, 8, 10]. This research will investigate the antioxidant activity of ylang.

2. Methods

This research method is observational research, cross sectional. The methodology of this research is that this research in vitro tests which include the detection total phenolic, antioxidant IC50- DPPH, and heart histopathologic features.

Medicinal materials that are used in humans need to be researched first for their effectiveness and safety, but including human subjects should only be done if the tested materials have passed the testing in the laboratory completely, followed by using experimental animals for feasibility and safety. In general, the human response to drug exposure is qualitatively similar to the animal response. One of the advantages of using experimental animals is that they can use one or several relatively high doses that induce signs of toxicity.

Rats (*Rattus norvegicus*) are animals that are commonly used in this study. *Rattus norvegicus* has a weight of 150-600 grams, a blunt nose and a body length of 18-25 cm, has a head and body that is shorter than its tail, and relatively small ears with a long body 20-23 mm. The interaction between toxicants and cells can result in the emergence of effects called toxicity. Toxicity test aims to determine the effects caused by the interaction of the toxicant and the cells, this test is based on toxicant exposure divided into acute toxicity, subacute toxicity, and subchronic toxicity.

Oral subacute toxicity test is a test to detect toxic effects that appear after administration of the test preparation with repeated doses given orally to test animals for part of the animal's life, but not more than 10% of the entire life of the animal. Test animals were given the preparation every day and observed every day to determine the presence of toxicity. The purpose of the oral subacute toxicity test is to obtain information on the presence of toxic effects on substances that are not detected in the acute toxicity test which is only carried out once the test preparation is administered. obtain information on doses that do not cause toxic effects or NOAEL (No Observed Adverse Effect Level), and study the cumulative effect and reversibility of the tested substance.

Observations of body weight were also carried out to determine the presence of toxic effects that occurred in white rats. Histopathological observations were carried out to determine the changes in the structure of the cells in the observed organs due to the toxicity of a compound. If the administration of the test material exceeds 7 days, then an observation is made on the organ weight, the toxic effect of a compound can be observed through the organ weight if the administration of the test material is carried out for a minimum of 7 days.

The relative weight of the organs is an important index to see the physiological and pathological state of the experimental animal's organs after exposure to the test preparations, the relative weight of the organs is the basis for diagnosing the presence or absence of organ damage due to metabolic reactions of toxic substances. The heart and lungs as the observed organs were weighed first to obtain absolute organ weights. Relative organ weight was obtained by dividing absolute organ weight by body weight.

The total number of samples used were 30 white rats. The repetition was done 4 times. Determination of the minimum number of samples using the experimental sample size formula from Federer. The number of

rats used was 5 for each study group (4 treatment groups, 1 positive control group, and 1 negative control group). There were 6 treatments with each treatment carried out 4 times, so that the samples used in this study amounted to a total of 30 white rats.

About 30 white rats (*Rattus norvegicus*) were acclimatized for 1 week before being used in the study, during which the rats were fed and drank according to the dose. To avoid bias towards body weight in rats, white rats (*Rattus norvegicus*) were weighed before receiving treatment, then randomly divided into 6 groups, each consisting of 5 males. The dose used in this study was obtained based on the smallest dose from the acute test of the *Cananga odorata* extract of 50 mg and the dose limit of 1000 mg/KgBW, the dose used was 100 mg; 300 mg; 500 mg/KgBW. This study has received approval from the Universitas Sumatera Utara Ethics Committee no. 1380/KEPK/USU/2021, date December 29th, 2021.

3. Results

The results of the examination of the total phenol of flower memories showed very low antioxidant activity based on the examination of total phenol and the IC₅₀ DPPH antioxidant test using a spectrophotometric device. The results of the spectrophotometric examination found that the total phenol was 1.06% (w/w) and the antioxidant IC₅₀-DPPH was 808.86 ppm (Fig. 1).

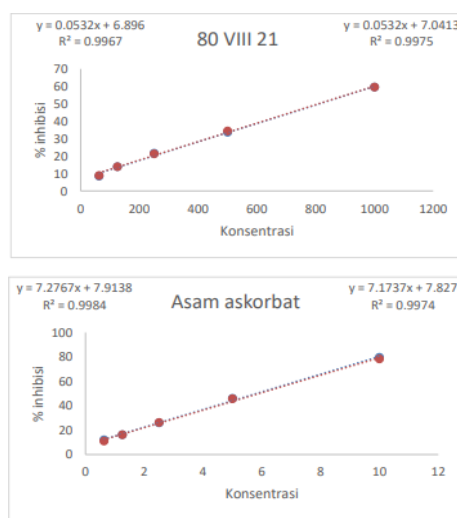


Figure 1. Antioxidant Curve

Research on the subacute toxicity of the ethanolic extract of *C. odorata* on cardiac histopathology (*Rattus norvegicus*) with the aim of obtaining information on the presence of toxic effects of substances that were not detected in acute toxicity tests and toxic effects after repeated exposure of the test preparations within a certain period of time through observation of toxicity symptoms, weight, body weight, relative organ weight, morphology and histopathology of the heart and lungs of white rats. This study used 30 male white rats (*Rattus norvegicus*) wistar strain which were divided into 6 groups, with 5 rats in each treatment group. The results of the study are as follows.

Results of Observation of Toxicity Symptoms in Rats

Observation of toxicity symptoms was carried out every day after extract induction for 28 days. Symptoms of toxicity that occurred in rats during subacute toxicity tests are presented in Table 1.

Tabel 1. Observation of Toxicity Symptoms

| Treatment | Score | Category |
|-----------|-------|-------------------------------------|
| C (-) | 1 | No indication of pain and no stress |
| C (+) | 1 | No indication of pain and no stress |
| T1 | 1 | No indication of pain and no stress |
| T2 | 1 | No indication of pain and no stress |
| T3 | 1 | No indication of pain and no stress |

Noted :

C (-) : Negative control with standard diet

C (+) : Positive control with high fat diet

T1 : Treatment 1 (*Cananga odorata* extract with 50 mg/KgBW weight)

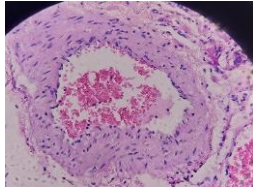
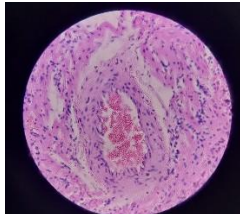
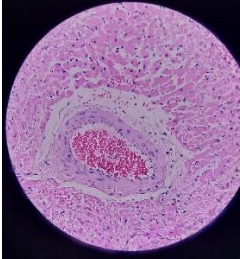
T2 : Treatment 2 (*Cananga odorata* extract with 300 mg/KgBW weight)

T3 : Treatment 3 (*Cananga odorata* extract with 500 mg/KgBW weight)

The characteristic of normal heart muscle is that each heart muscle has only one (or two) pale nuclei located in the middle. Surrounding the muscle cells is a connective tissue endomysium that contains a wide network of capillaries. The presence of transverse dark lines that cross the heart cells at irregular intervals is called the intercalated disc. The intercalated disc is a junctional complex located at the junction of adjacent cardiac muscle cells, has many desmosomes and adherentes fascia which functions to tightly bind cardiac cells to prevent these cells from being separated due to constant contraction activity. The longitudinal portion of each disc has many gap junctions that function for continuous ion exchange in adjacent cells.

The results showed that the nucleus is located in the middle, oval in shape, branching which is characteristic of the heart muscle, and intercalated discs are also seen. Histopathological changes that occurred in the form of hydropic degeneration in the control, treatment, and satellite groups. There is a nucleus that is larger and swollen than the normal nucleus, hydrophilic degeneration has the characteristics of swollen cells.

Table 2. Histopatology features

| No | No Preparat | Name of treatment | Enlargement | Microscopic picture | Microscopic |
|----|-------------|------------------------|-------------|--|---|
| 1 | 321 | Control Negative M1-1 | 400x |  | Plaque : Negative (-) Thrombus : Negative (-) Calcification: Negative (-) |
| 2 | 327 | Control Positif M2 - 2 | 400x |  | Plaque : Negative (-) Thrombus : Negative (-) Calcification: Negative (-) |
| 3 | 331 | M3-1 | 400x |  | Plaque : Positif (-) Thrombus : Negative (-) Calcification: Negative (-) |

4. Discussion

Organic drugs have advantages over inorganic drugs, including relatively few side effects, synergistic effects in their content, and more suitable for metabolic and generative diseases. The use of organic drugs has been accepted in almost all countries, the factors for the increase in the use of organic drugs in developed countries are a longer life expectancy when the prevalence of chronic diseases increases, the failure to use inorganic drugs for certain diseases including cancer and wider access to information about drugs. organic worldwide. However, its use must be appropriate, which includes the correctness of the ingredients, the accuracy of the dose, the time of use, the accuracy of the method of use, the accuracy of reviewing the information, and without the abuse of the organic drug itself [1, 2, 10, 11].

The use of organic medicine or commonly called traditional medicine namely *C. odorata* as an anti-inflammatory must go through a series of tests so that the results obtained are in line with expectations and

can be ensured of safety, one of which is preclinical testing. The subacute toxicity test is one of the preclinical tests that aims to see the toxic effects caused by the administration of *C. odorata* for a long period of time [10-12]. The selection of male white rats was caused by the nature of male rats which was not affected by the reproductive cycle. The presence of an estrus cycle in female rats will affect kidney function and nitric oxide activity. The estrus cycle in virgin female rats lasts for 4-5 days consisting of proestrus, estrus, and diestrus. When proestrus estrogen reaches its maximum level, blood vessels will narrow during the process of reduced circulating estradiol due to aromatase inhibition which causes an increase in total nitric oxide production in female rats. According to nitric oxide, it will initiate an acute inflammatory response in the lungs, if there are free radical compounds in the form of nitric oxide into the lung tissue, it will cause an increase in the number of macrophages and/or neutrophils that function to phagocytize foreign particles. This will bias the histopathological and physiological changes of white rats if female white rats are used as experimental animals [5, 10, 12]. Giving the extract for 28 days did not cause death in white rats, indicating that the test preparation in the form of *C. odorata* extract was not toxic. Rats are also not in a state of stress and pain. In addition to appetite, the characteristics of the condition of rats, whether under stress or not, can be seen from the observation of toxicity symptoms [8, 9, 10, 13].

Symptoms of toxicity are parameters of the presence of toxic effects that are easily observed. Stressed rats can show symptoms of very coarse hair, sunken eyes, slow or unresponsive movements, slouching, large abdominal mass, and aggressive behavior. While mice that are not stressed and indicate no pain will be seen in well-groomed hair, in a state of calm or sleep, normal appetite, spinal vertebrae and dorsal pelvis are not prominent. The results showed that the rats showed no stress and did not experience pain in all treatment groups. This indicated that the administration of *C. odorata* extract had no effect on white rats indicated by the absence of toxicity symptoms that appeared in the control, treatment, and satellite groups.

5. Conclusion

The findings of this study indicate that administering *C. odorata* extract for 28 days did not cause death or visible signs of toxicity in white rats. Throughout the treatment period, the rats showed no behavioral or physical symptoms typically associated with stress or pain. Their general condition, including grooming behavior, appetite, and posture, remained normal across all groups. These observations suggest that the extract was well tolerated and did not produce toxic effects, supporting its safety in the tested dose and duration.

6. Data Availability Statement

The datasets generated and analyzed during the current study are not publicly available due to privacy and ethical considerations but are available from the corresponding author upon reasonable request.

7. Ethical Statement

This study was approved by the Ethics Committee for Health Research at Universitas Sumatera Utara under approval number: 1380/KEPK/USU/2021, dated December 29th, 2021.

8. Author Contributions

All authors contributed to the design and implementation of the research, data analysis, and finalizing the manuscript.

9. Funding

No funding.

10. Conflict of Interest

Authors declares no conflict of interest.

References

- [1] Jin J, Kim MJ, Dhandapani S, et al. The floral transcriptome of ylang ylang (*Cananga odorata* var. *fruticosa*) uncovers biosynthetic pathways for volatile organic compounds and a multifunctional and novel sesquiterpene synthase. *J Exp Bot*. 2015;66(13):3959–75.
- [2] Lee K, Lee JH, Kim SI, Cho MH, Lee J. Anti-biofilm, anti-hemolysis, and anti-virulence activities of black pepper, cananga, myrrh oils, and nerolidol against *Staphylococcus aureus*. *Appl Microbiol Biotechnol*. 2014;98(22):9447–57.
- [3] Matsumoto T, Nakamura S, Fujimoto K, et al. Structure of constituents isolated from the flower buds of

- Cananga odorata* and their inhibitory effects on aldose reductase. *J Nat Med.* 2014;68(4):709–16.
- [4] Matsumoto T, Nakamura S, Nakashima S, et al. Lignan dicarboxylates and terpenoids from the flower buds of *Cananga odorata* and their inhibitory effects on melanogenesis. *J Nat Prod.* 2014;77(4):990–9.
- [5] Zhang X, Herger AG, Ren Z, Li X, Cui Z. Resistance effect of flavonols and toxicology analysis of hexabromocyclododecane based on soil-microbe-plant system. *Chemosphere.* 2020;257:127248.
- [6] Phatchana R, Thongsri Y, Yenjai C. Canangalial C-H, juvenile hormone III analogues from the roots of *Cananga latifolia*. *Fitoterapia.* 2016;114:45–50.
- [7] Qin XW, Hao CY, He SZ, et al. Volatile organic compound emissions from different stages of *Cananga odorata* flower development. *Molecules.* 2014;19(7):8965–80.
- [8] Soonwera M. Efficacy of essential oil from *Cananga odorata* (Lamk.) Hook.f. & Thomson (Annonaceae) against three mosquito species *Aedes aegypti* (L.), *Anopheles dirus* (Peyton and Harrison), and *Culex quinquefasciatus* (Say). *Parasitol Res.* 2015;114(12):4531–43.
- [9] Tan LT, Lee LH, Yin WF, et al. Traditional uses, phytochemistry, and bioactivities of *Cananga odorata* (Ylang-Ylang). *Evid Based Complement Alternat Med.* 2015;2015:896314.
- [10] Liu C, Wu H, Wang L, et al. *Farfarae Flos*: A review of botany, traditional uses, phytochemistry, pharmacology, and toxicology. *J Ethnopharmacol.* 2020:113038.
- [11] Benini C, Mahy G, Bizoux JP, et al. Comparative chemical and molecular variability of *Cananga odorata* (Lam.) Hook.f. & Thomson forma genuina (ylang-ylang) in the Western Indian Ocean Islands: implication for valorization. *Chem Biodivers.* 2012;9(7):1389–402.
- [12] Neumann NR, Thompson TM. Medical toxicology education and global health: it is still a world of limited resources in low- and middle-income countries. *J Med Toxicol.* 2020.
- [13] Yang H, Kim HS, Jeong EJ, et al. Plant-derived juvenile hormone III analogues and other sesquiterpenes from the stem bark of *Cananga latifolia*. *Phytochemistry.* 2013;94:277–83.