

Management of Congenital Aural Atresia: A Case Report

Yuli Tetriana Sari, Delfitri Munir

Department of Otorhinolaryngology Head and Neck Surgery, Faculty of Medicine Universitas Sumatera Utara, Medan, Indonesia

Abstract. Congenital Aural Atresia (CAA) is the failure of development of the external auditory canal. It usually occurs in conjunction with microtia, which is malformation of the auricle due to the failure of development of the external ear. The evaluation and treatment of aural atresia present a number of challenges to the otologic surgeon. Computed tomography also plays a pivotal role in planning the surgery and grading the outcome of the surgery in congenital aural atresia. We report a case of unilateral congenital aural atresia and microtia and did a canalplasty and tympanoplasty in this patient

Keyword: Congenital aural atresia, Microtia, Canalplasty

Received 30 August 2019 | Revised 26 September 2019 | Accepted 30 September 2019

1 Introduction

Congenital malformation of external ear is often associated with malformation of middle and inner ear. Incidence of canal atresia is in 10 000 – 20 000 live births with unilateral being more common than bilateral. External ear atresia is mostly bony rather membranous; bony atresia of external ear is regularly associated with malformation of middle ear cavity and structures of middle ear. The majority of the cases are unilateral and male-predominant, 2.5 times more prevalent than female. It is often described that cases on the right side are more common. Most case of atresia are associated with microtia and the degree of atresia is correlated with the degree of auricular deformity [1,2].

CT scan, especially, high resolution CT scan is of great importance to delineate the extent of disease process and also to know the ossicular-chain status, condition of inner ear, and condition of seventh and eighth nerves. CT scan in case of congenital aural atresia also helps prognostically to predict the outcome of surgical correction [2].

*Corresponding author at: Faculty of Medicine, Universitas Sumatera Utara, Medan, Indonesia

E-mail address: ulie8783@gmail.com

Auditory assessment in patients with unilateral atresia is usually straightforward. Behavioral audiometry can be used in most cases, although auditory brainstem response testing may be necessary in young infants or children who are difficult to test. Patients with bilateral atresia present more of a challenge because of the masking dilemma. In patients with unilateral atresia, it is not unusual for the seemingly normal contralateral ear to have a hearing loss [3,4].

2 Case Report

SD, 8 year old female, came to USU Hospital on April 9th 2019, with main complaint of microtia in the right ear. On physical examination, there was no External Auditory Canal (EAC) (figure 1) in the right ear and hearing loss was found. The patient has no complaint about the left ear eventhough she has a history of ear discharge at 3 years old.

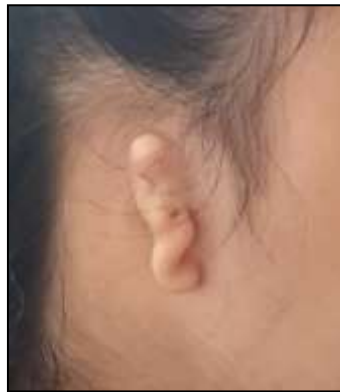

Figure 1. Microtiagrade III in the Right Ear

Actually we did the audiometry test before the surgey but the result was disappear. The temporal CT-Scan (figure 2) showed the disappearance of mastoid air cell in the both side especially in the right side. Ossicles were clear; and Internal Auditory Canal (IAC) in right and left were normal. There were no destruction from the right and left os temporalis. Right EAC was absenced, auricle on the right ear is small. Left EAC was normal. Conclusion was bilateral mastoiditis, atresia external auditory canal on the right ear and right microtia.

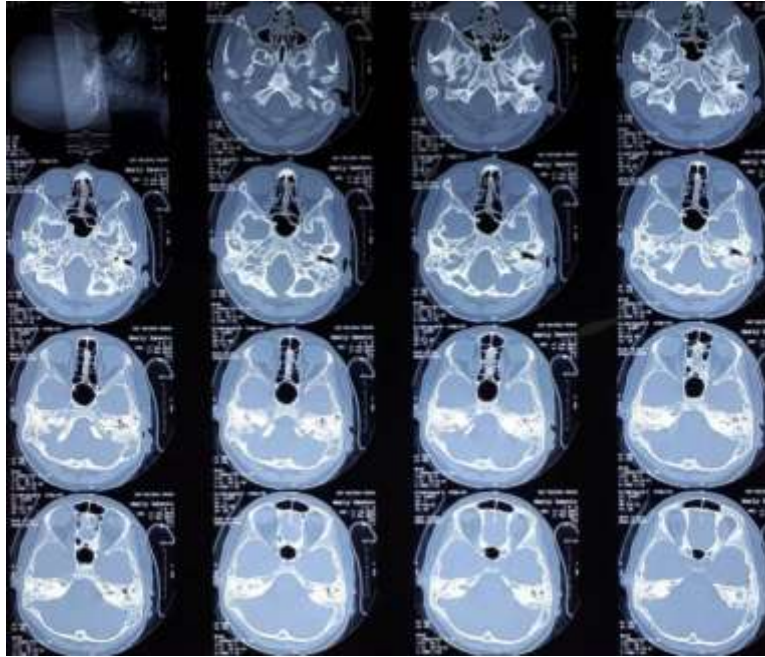


Figure 2. CT-Scan of the Temporal Bone

The patient was diagnosed as unilateral congenital aural atresia in the right ear and microtia grade III. The patient underwent right canalplasty and tympanoplasty on April 10th 2019.

We made a landmark in the postauricular of the right ear and did the infiltration with Pehacain 1:200.000. Based of the landmark we did the incision layer by layer and took the graft from musculus temporalis.

We drilled the atretic bones and removed it for the external canal and we found ossicular chain and normal (figure 3). The facial nerves were exposed. Graft from musculus temporalis was placed over the mobilized ossicular chain. To made epithelization of the new tympanic membrane we covering the fascia graft with skin graft (pedicle flap) and compressed with gelfoam (figure 5).

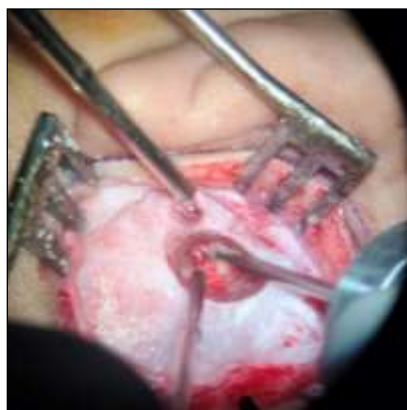

Figure 3. Drilling the Atretic Bone to External Ear Canal

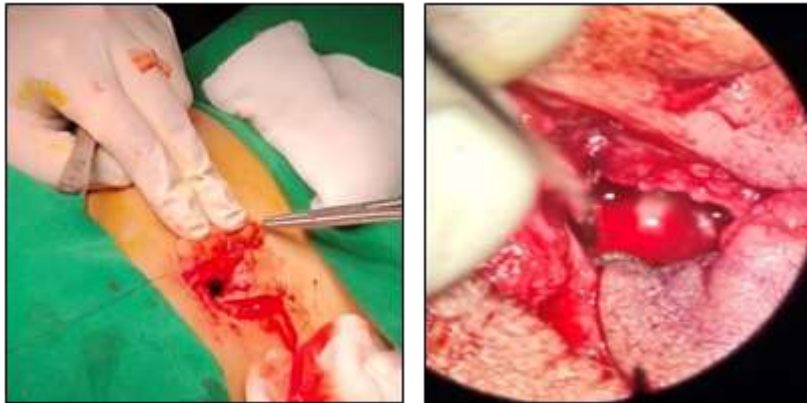

Figure 4. Covering the Fascia Graft with Skin Graft

After surgery, the patient was given IVFD RL, antibiotic, steroid, analgetic and antihemorrhagic administered intravenously. We found a facial palsy one day after surgery with House-Brackmann II and we consult to the physiotherapy (figure 5).



Figure 5. The Patient had a House-Brackmann II One Day After Surgery

One month after surgery the patient got better. The facial palsy did not found anymore, she can smile and close her eyes perfectly (figure 6). Wound of the operation was dry, headache and dizziness did not found.



Figure 6. Facial Palsy did not Found Anymore

We did pure tone audiometry after the surgery and the result is moderate-severe hearing loss in the right ear (figure 7).

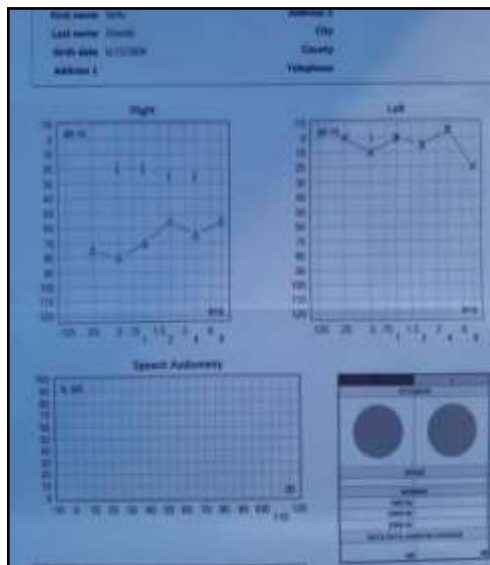


Figure 7. Pure Tone Audiometry One Month After Surgery

3 Discussion.

Congenital Aural Atresia (CAA) refers to a spectrum of ear deformities present at birth that involves some degree of failure of the development of the external auditory canal (EAC). Microtia has an incidence at 1 in 7 000 to 8 000 births in the general population. The majority of the cases are unilateral and males are affected more commonly, and the reported ratio of right to left bilateral is approximately 5:3:1 with bilateral deformity occurring in only 10% of patients [5,6]. Depending on the degree of the abnormality, the microtic ear may be classified into three grades. In grade I, the auricle is developed and though misshapen, has a readily recognizable, characteristic anatomy. In grade II, the helix is rudimentary and the lobule developed. In grade III, an amorphous skin tag is present [6]. In this case, we have a female patient with unilateral congenital aural atresia in the right ear and microtia grade III.

The majority of the patients (80-90%) have moderate-severe to severe grade conductive hearing loss on the disease side. Patients with unilateral aural atresia usually have normal hearing on the unaffected side, unless an underlying syndrome is associated, for example, Goldenhar syndrome. Despite intact hearing on the contralateral side, it has been well established that patients with unilateral hearing loss have significant difficulties in academic performance and communication. They also suffer from lower self-esteem and at least 25% of the patient's parents and teachers report behavioral problems and academic performance issues [7,8]. In this case the patient complaint a hearing loss. One month after surgery the pure tone audiometry result is moderate-severe conductive hearing loss in the right ear.

Pre operative high resolution CT of the temporal bone plays a central role in evaluating surgical candidates and planning operation [2,9]. In our case we did the CT-Scan of temporal bone and the result is bilateral mastoiditis, atresia external auditory canal on the right ear and right microtia.

Microtia surgery is technically difficult and not infrequently, the results are somewhat disappointing. An alternative technique for the treatment of severe grade III microtia is to use a lifelike prosthetic ear. In this patient we planned to use a prosthetic ear.

Principally, treatment of the atresia ear canal is surgical. The involved stenotic tissue must be removed. The bony canal must be generously widened with a burr because subsequent osteoblastic activity may lead to restenosis, especially in children. Canalplasty or atresioplasty the reconstruction of the external auditory canal, was first attempted by Kiesselbach in 1883. Patients suitable for this surgery must have abnormally functioning cochlear, as demonstrated by CT and audiogram. Nowadays, candidates for canalplasty are selected according to Jahrsdoerfer classification. Modern technology has brought more treatment option for congenital aural atresia. Implantable hearing aids including Bone Anchored Hearing Aid (BAHA), Bonebridge (BB), Vibrant Soundbridge (VSB) offer more choices for patient with congenital aural atresia [1,5,10,11]. In our patient we did a surgery with canalplasty and tympanoplasty type 2 procedure and the patient did not choose for the modern technology for the treatment.

4 Conclusion.

We report a case of 8 years old female with main complaint is congenital aural atresia in the right ear and we did a surgery with canalplasty and tympanoplasty type 2 procedure.

REFERENCES

- [1] Kelley P.E. and Scholes M.A., "Microtia and congenital aural atresia," *Otolaryngologic Clinics of North America*. Vol 40. No 1. pp 61-80, 2007.
- [2] Sohal B.S., Aggarwai P., Goyal J.P. and Gupta A., "Congenital cholesteatoma with canal atresia: three case report," *Indian Journal of Otology*. Vol. 19. Issue. 3. pp. 146-8, 2013.
- [3] Parisier S.C., Fayad J.N. and Kimmelman C.P., "Microtia, canal atresia and middle ear anomalies," In: Ballenger's Otorhinolaryngology Head and Neck Surgery. Sixteenth Edition. Chapter 42. pp. 997-1008, 2003.
- [4] Lambert P.R., "Congenital malformation of the ear," In: Bailey's Head & Neck Surgery Otolaryngology. Fifth Edition. Vol 1. pp. 2384-98, 2014.
- [5] Lo Jack F.W. et al., "Contemporary hearing rehabilitation options in patients with aural atresia," Hindawi Publishing Corporation Biomed Research International. Volume 2014.
- [6] Singh R.K. et al., "Case of unilateral congenital aural atresia & microtia with cholesteatoma," *Journal of Otolaryngology Advances*. Vol. 2. Issue. 1. pp. 1-6, 2017.
- [7] Siegert R., Mathheis S. and Kasic J., "Fully implantable hearing aids in patients with congenital auricular atresia," *The Laryngoscope*. Vol. 117. No. 2. pp. 336- 40, 2007.
- [8] Tye-Murray N., Fu Q. and Lieu J.E., "Longitudinal study of children with unilateral hearing loss," *The laryngoscope*. Vol. 123. No. 9. pp. 2088-95, 2012.
- [9] Gassner E.M., Mallouhi A. and Jaschke W.R., "Preoperative evaluation of external auditory canal atresia on high-resolution CT," *AJR* 2004. pp.1305-12, 2004.
- [10] Bajin M. D et al., "Management of acquired atresia of the external auditory canal," *The Journal of International Advanced Otology*. pp 147-50, 2015.
- [11] Bouhabel S., Arcand P. and Saliba I., "Congenital aural atresia: bone anchored hearing aid vs external auditory canal reconstruction," *International Journal of Pediatric Otorhinolaryngology*. Vol .76. No. 2. pp 272-7, 2012.