

## Review Article

# Iron Overload Cardiomyopathy

Retno Eka Sari<sup>\*1</sup>, Wahyudi<sup>2</sup>

<sup>1</sup>Undergraduate Program of Medicine, Department of Internal Medicine, Faculty of Medicine, Universitas Andalas, Padang, 25175, Indonesia

<sup>2</sup>Division of Cardiology, Department of Internal Medicine, Faculty of Medicine, Universitas Andalas, Padang, 25175, Indonesia

\*Corresponding Author: retnosari530@gmail.com

### ARTICLE INFO

#### Article history:

Received 1 August 2024

Revised 17 August 2024

Accepted 29 August 2024

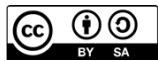Available online 5 September 2024

E-ISSN: 2622-1357

P-ISSN: 2622-9234

#### How to cite:

Retno Eka Sari, Wahyudi, "Iron Overload Cardiomyopathy", SUMEJ, Vol. 07, No. 03, September 2024.



This work is licensed under a Creative Commons Attribution-ShareAlike 4.0 International.  
<https://doi.org/10.32734/sumej.v7i3.17796>

### ABSTRACT

**Background:** Iron overload cardiomyopathy is a condition of excessive iron accumulation in cardiomyocytes due to abnormal iron absorption or repeated blood transfusion. **Objective:** This literature review was to discuss about iron overload cardiomyopathy. **Methods:** This was a literature review that explored about iron overload cardiomyopathy based on other research. **Results:** In the early stages, the patient may be asymptomatic with good ventricular systolic function. Iron deposit in ventricular cause dyspnea on effort due to left ventricular systolic dysfunction then in atrial cause atrioventricular block and supraventricular arrhythmic. For severe symptom due to dilated cardiomyopathy is characterized by left ventricular dilatation and risk of sudden cardiac death. Diagnosis of iron overload cardiomyopathy can be made if there is evidence of heart disease, the presence of iron overload (serum ferritin > 300 ng/mL and transferrin saturation > 55%) and cardiac siderosis with cardiac MRI T2 \* < 20 ms as gold standard. Patient management involves lowering systemic iron levels and preventing iron entry into cardiomyocytes. Therapy with phlebotomy or iron chelation as indicated. **Conclusion:** Administration of calcium channel blockers and resveratrol antioxidant therapy may be considered to reduce morbidity and mortality due to cardiac siderosis.

**Keywords:** calcium channel blocker, cardiomyopathy, iron overload

## 1. Introduction

Iron overload cardiomyopathy (IOC) is a condition of excessive iron accumulation in cardiomyocytes due to abnormal iron absorption such as genetic disorders in primary hemochromatosis or secondary to repeated blood transfusions and parenteral iron therapy. The study of Aydinok et al (2015) in 925 iron overload patients with transfusion dependent anemia found as many as 36.7% with cardiac siderosis. The study of Chapchap et al (2023) showed that iron deposits usually occur first in the liver then pancreas and finally the heart [1, 2, 3].

In the early stages of the disease, patients may be asymptomatic with good ventricular systolic function. As the disease progresses, iron deposits occur in the ventricular myocardium, with symptoms of breathlessness on exertion due to left ventricular (LV) systolic dysfunction. Iron deposits in the conduction system then lead to atrioventricular (AV) block and arrhythmias. This condition can worsen become dilated cardiomyopathy characterized by left ventricular dilatation, paroxysmal atrial fibrillation leading to myocardial damage and increased risk of sudden cardiac death (SCD) in patients with iron overload.[4] The gold standard is T2\* cardiac MRI. A value of 20 ms is considered the threshold for myocardial siderosis. The diagnosis of IOC is confirmed if there is evidence of heart disease, especially LV diastolic dysfunction with restrictive filling or LV remodeling with dilatation of the heart chambers and decreased LV ejection fraction, the presence of iron overload (serum ferritin >300 ng/mL and transferrin saturation >55%) and cardiac siderosis (cardiac MRI T2\* <20 ms) [5,6]. Management of patients with iron overload is principally by lowering systemic iron levels or

preventing iron entry into tissues, because humans do not have an endogenous mechanism to remove excess iron. Phlebotomy and iron chelation are two ways to lower systemic iron [5]. As for preventing iron entry into tissues, administration of calcium channel blockers (CCBs) can be considered [7-11]. In addition, resveratrol therapy such as the study of Das et al (2018) also provides a new therapeutic strategy for IOC [12].

## 2. Methods

### 2.1. Physiology of iron metabolism

#### 2.1.1. Iron distribution

Adult men normally have 35 to 45 mg of iron per kilogram of body weight, while premenopausal women have lower amounts due to recurrent menstruation. Of the 3500 mg of total iron in the body, erythrocytes and liver contain the highest amounts of iron at 1800 mg and 1000 mg, respectively. In the absence of bleeding, only a small proportion of iron is lost due to desquamation of epithelial cells at 1-2 mg/day. This loss is replaced by absorption of iron from food. The iron present in the body is constantly taken up from erythrocytes and macrophages as the main recycling process. Thus under normal circumstances, less than 10% of the daily iron requirement is taken from food [2, 13].

#### 2.1.2. Iron Absorption and Regulation

Iron comes in two different forms: organic (heme iron) and inorganic (ionic iron). The inorganic form of iron is absorbed at the apical membrane of duodenal epithelial cells, duodenal cytochrome b (DCTYB) reduces  $Fe^{3+}$  to  $Fe^{2+}$  form then leaves the epithelial cells at the basolateral membrane through iron transporter (ferroportin) and oxidation by hephaestin to  $Fe^{3+}$ . The organic form of iron (heme) is absorbed through the heme/folate transporter 1 (HCP1) at the apical membrane [2, 13]. Inorganic iron absorption is regulated by the hormone hepcidin which inhibits iron transfer and promotes ferroportin degradation. Hepcidin is produced in the hepar as a negative feedback response to increased transferrin saturation. When plasma iron content is low, iron complexes cannot form so no hepcidin is produced. Whereas in the presence of holo transferrin, iron complex formation occurs which triggers the expression of the hepcidin gene (Hamp). Disruption of this process leads to dysregulation of iron absorption resulting in iron overload or iron deficiency [2].

#### 2.1.3. Cellular Iron Metabolism

Intracellular iron homeostasis is maintained by iron absorption, loss, storage and mobilization. Iron uptake occurs through several different mechanisms such as transferrin-mediated endocytosis, divalent metal transporter 1 (DMT1), voltage gated calcium channels especially L-type and T-type (LTCC and TTCC) and heme/folate transporter (HCP1). Endocytosis, Transferrin- and DMT1-mediated endocytosis is the mechanism of iron uptake in all tissues, whereas  $Fe^{2+}$  influx through voltage gated calcium channels is limited to excitable cells such as cardiomyocytes and neurons. Within the cell,  $Fe^{2+}$  is utilized for ferroprotein synthesis and transported to the mitochondria via mitoferrin to form iron-sulfur complexes (Fe-S), heme synthesis and DNA repair enzymes [2, 14].

#### 2.1.4. Post Translational Regulation of Cellular Iron Metabolism

In general, cellular iron homeostasis is regulated by the iron response elements/iron regulatory proteins (IRPs/IREs) system that ensures iron demand without cellular iron toxicity. Under low  $Fe^{2+}$  conditions in the cell, IRP proteins can bind to IREs to suppress ferritin mRNA translation and TFR1 mRNA stabilization. This leads to the release of iron from the depot and increased cellular iron uptake. Meanwhile, the increased  $Fe^{2+}$  concentration in the cell forms an Fe-S complex that binds to IRP and prevents the formation of IRP/IRE [14].

## 2.2. Iron overload cardiomyopathy

### 2.2.1. Definition of iron overload cardiomyopathy

The American Heart Association (AHA) defines iron overload cardiomyopathy (IOC) as excessive iron accumulation in cardiomyocytes due to abnormal iron absorption as in primary hemochromatosis or due to repeated blood transfusions or high parenteral iron therapy. Other definitions focus on clinico-pathological factors, namely the presence of cardiac systolic or diastolic dysfunction secondary to increased iron accumulation in the myocardium in the absence of other accompanying processes, a form of dilated cardiomyopathy with remodeling LV chamber dilatation and decreased LV ejection fraction [4,5,6].

## 2.3. Etiology of Iron Overload Cardiomyopathy

### 2.3.1. Primary Hemochromatosis

Primary hemochromatosis is caused by mutations in five genes encoding various iron transport and iron-

sensing proteins resulting in hepcidin deficiency. Loss of function of human hemochromatosis protein (Hfe), hemojuvelin (Hjv) (formerly known as Hfe2) and transferrin receptor 2 (Tfr2), results in hemochromatosis types 1, 2A and 3. Increased transferrin saturation above 45% leads to the appearance of non-transferrin bound iron (NTBI) and transferrin saturation above 80% leads to the formation of labile plasma iron that can generate reactive oxygen species (ROS). Mutation of the gene encoding hepcidin (Hamp) causes hemochromatosis type 2B and mutation of the gene encoding ferroportin (Slc40a1) is classified as hemochromatosis type 4. Clinically, primary hemochromatosis type 1 has a long asymptomatic phase and clinical manifestation is generally at the age of 30-40 years in men and 40-50 years in women. Types 2A, 2B and 3 have an early onset of disease before the age of 20-30 years [2].

### 2.3.2. Secondary Iron Overload

Iron overload is secondary to complications of hematological disorders or hemodialysis. Hematological disorders such as hereditary anemia (e.g. thalassemia and sickle cell disease) and acquired anemia (e.g. aplasia anemia and myelodysplastic syndrome). These conditions require repeated blood transfusions of 2 units per month, resulting in 400-500 mg of iron per transfusion or about 20 g in 4 years which is 10 times more than the normal iron content of the adult body. Continued accumulation of iron in the body can cause liver and heart damage due to iron toxicity [2]. End-stage renal disease patients who are given erythropoiesis stimulation therapy and parenteral iron are at double risk of iron deficiency on the one hand and iron overload (due to excessive iron supplementation) on the other. Both risks must be carefully controlled. However, the iron overload that may arise in dialysis patients is mostly confined to the liver, while the heart is relatively unaffected [2].

### 2.3.3. Pathogenesis of Iron Overload Cardiomyopathy (IOC)

Non-transferrin bound iron (NTBI) labile in plasma accelerates intracellular iron deposits, especially cells with calcium channels. Cardiac cells contain voltage gated calcium channels, especially high levels of functional LTCC and TTCC, making them highly susceptible to iron overload. The accumulation of NTBI in cardiac cells leads to the production of ROS and if ROS production exceeds the capacity of the endogenous antioxidant system, ROS can damage many proteins, nucleic acids and lipids. In the heart, oxidative stress causes impaired excitation-contraction coupling, suppresses Sarcoplasmic Ca<sup>2+</sup>-ATPase 2 (SERCA2) function leading to increased cytoplasmic calcium resulting in impaired relaxation and later contractility and lipid peroxidation causes membrane damage including mitochondrial membranes leading to inhibition of oxidative phosphorylation, ATP deficiency, direct DNA damage and mitochondrial DNA (mtDNA) [2, 14, 15]. Another pathogenesis is iron-mediated cell death called ferroptosis. Studies in the IOC mice model induce caspase-3 activation causing mitochondrial dysfunction resulting in apoptosis. In addition, NTBI directly activates fibroblasts that promote proliferation and differentiation into myofibroblasts that increase fibrosis in the heart [2, 14, 16].

### 2.3.4. Clinical Manifestations of Iron Overload Cardiomyopathy

Asymptomatic patient since ventricular systolic function is still good in the early. As the disease progresses, iron deposits occur in the ventricular myocardium, and patients may experience shortness of breath on exertion due to left ventricular (LV) systolic dysfunction. Iron deposits in the conduction system can cause nodal abnormalities resulting in arrhythmias. This condition can worsen into dilated cardiomyopathy characterized by left ventricular dilatation and paroxysmal atrial fibrillation leading to myocardial damage and increased risk of sudden cardiac death (SCD) in patients with iron overload. Severe cardiac distress may occur in the pericardium and most cases are asymptomatic [4].

### 2.3.5. Diagnosis of Iron Overload Cardiomyopathy

Anamnesis, physical examination, standard ECG and thorax X-ray are performed annually at initial evaluation and screening of patients unless cardiac abnormalities or siderosis are found. History of patients with hemoglobinopathies, myelodysplastic syndrome (MDS) or transfusion-dependent anemia hereditary or acquired and primary hemochromatosis. Cardiac symptoms such as left or right heart failure may be found in patients, along with other symptoms associated with extra-cardiac organ damage due to iron overload (hepatic dysfunction, diabetes mellitus, hypogonadal, other endocrine disorders and arthritis). Typical skin pigmentation like bronze hue or slate gray as a specific sign is usually associated with moderate to severe iron overload [5].

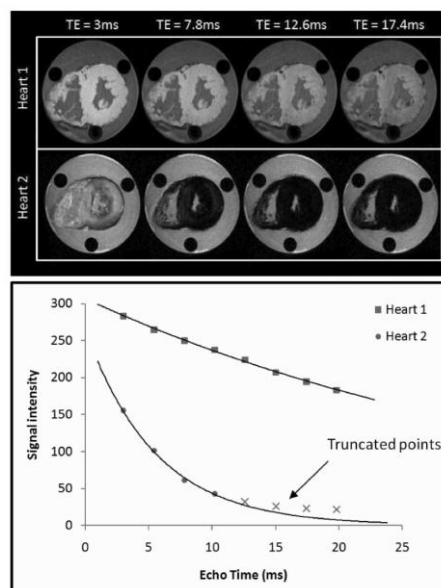
Basic laboratory test to confirm iron overload include serum ferritin and transferrin saturation. Complete blood examination, Hb electrophoresis, liver function and endocrine tests to assess underlying abnormalities

and potential organ damage due to iron overload. Genetic testing for confirmation of hereditary disorders especially in hemoglobinopathies or primary hemochromatosis. A standardized electrocardiogram (ECG) is required for identification of paroxysmal atrial fibrillation and bradyarrhythmic that become clinical phenotypes in IOC. Thorax X-ray shows cardiomegaly due to LV enlargement in the dilated phenotype of IOC, signs of pulmonary congestion in cases with left heart failure or left atrial or right ventricular enlargement with or without signs of pulmonary hypertension in the restrictive phenotype [5].

Echocardiography with left and right ventricular systolic and diastolic function abnormalities, pericardial and valvular involvement can be found. Impaired LV diastolic function shows a pseudonormal or restrictive pattern with or without left atrial and right ventricular dilatation, increased pulmonary artery pressure and preserved LVEF. Although echocardiography can identify myocardial structural abnormalities due to iron overload, it cannot accurately predict myocardial iron content [5,17].

Cardiac T2\*MRI is the gold standard in quantitative assessment of cardiac iron deposits. It accurately quantitatively assesses myocardial and hepatic iron deposits. The T2\* relaxation time is mainly influenced by iron in the form of hemosiderin and not ferritin. Cardiac T2\*MRI examination is a non-invasive and sensitive technique for early detection of siderosis and therapeutic monitoring. The Chinese study by Yang et al (2014) on T2\*MRI assessment of thalassemia major patients showed that cardiac siderosis can occur at a younger age than previously reported. They suggested that the first screening for cardiac T2\* MRI should be done as early as 6 years of age [18,19].

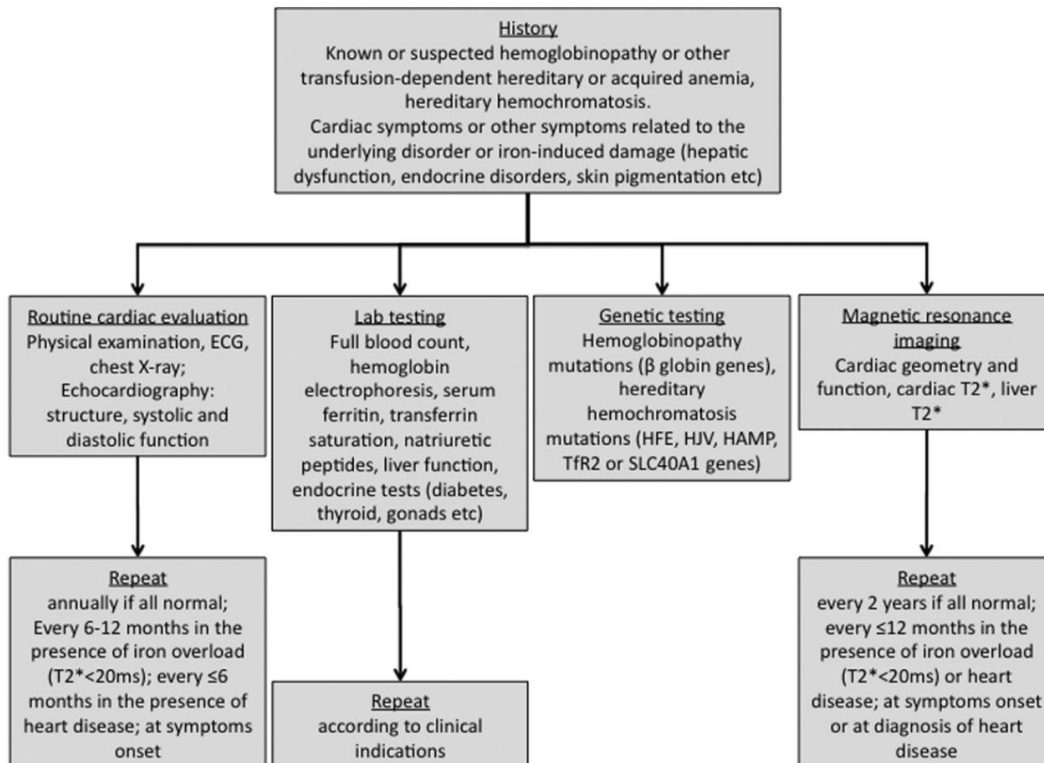
T2\* values < 20 ms indicate the presence of myocardial siderosis, while T2\* values < 10 ms indicate severe iron overload. The resultant T2\* value has an inverse correlation with LVEF and is associated with an increased annual risk of heart failure or arrhythmia. In a prospective study of 652 patients with thalassemia major, the incidence of heart failure within 1 year was 47%, 21%, and 0.2% in patients with T2\* < 6 ms, 6 to 10 ms, and > 10 ms, respectively. Arrhythmias occurred in 19% of patients with T2\* < 6 ms, 18% of patients with T2\* 6 to 10 ms and 4% of patients with T2\* >10 ms. However, the widespread application of cardiac T2\* MRI is still limited due to lack of equipment availability in developing countries [5,18].



**Figure 1.** Cardiac T2\*MRI

The diagnosis of IOC is established if there is evidence of heart disease, especially LV diastolic dysfunction with restrictive filling or LV remodeling with dilatation of the heart chambers and decreased LV ejection fraction, the presence of iron overload (serum ferritin > 300 ng/mL and transferrin saturation > 55%) and cardiac siderosis (cardiac MRI T2\* < 20 ms). The study of Wahidiyat et al (2018) showed that serum ferritin levels correlated weakly with cardiac T2\* MRI results, moderate correlation with liver and pancreas T2\* MRI results. In line with the study of Atmakusuma et al (2021) at RSCM in adult thalassemia patients, it shows that serum ferritin levels are weakly correlated with iron toxicity and cardiac systolic function. Although the correlation between serum ferritin and cardiac iron or the presence of IOC is weak, ferritin concentrations >2500 ng/mL still indicate the presence of significant total body iron content with a high risk of heart disease. The study of Eghbali et al (2020) concluded that the negative correlation of serum ferritin with cardiac T2\*MRI in patients with ferritin levels > 2000 ng/mL had cardiac abnormalities. The ferritin threshold of 2027 ng/mL

in the study of Khezri et al (2022) showed a sensitivity of 50% and specificity of 77.4% for cardiac siderosis. Therefore, serum ferritin level and transferrin saturation should not be used alone to assess the degree of hemosiderosis in various organs and it is recommended that cardiac T2\* MRI examination at least once to assess iron accumulation in organs. In addition to identifying patients with IOC, it is very important to identify those at risk, namely patients with iron overload with or without cardiac siderosis and patients with conditions that could potentially lead to iron overload, as appropriate measures can prevent the development of IOC [5,20,21,22,23,24].



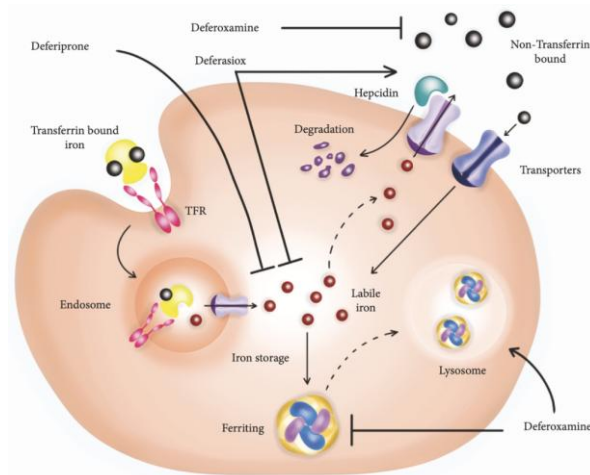
**Figure 2.** Diagnostic approach of patient suspected iron overload cardiomyopathy

### 3. Results and Discussion

#### 3.1. Management of iron overload cardiomyopathy

Humans have no endogenous mechanism to remove excess iron, so iron overload is managed by lowering systemic iron levels or preventing iron entry into tissues. Phlebotomy and iron chelation are two ways to lower systemic iron. Phlebotomy is mainly used to treat primary hemochromatosis. Patients with primary hemochromatosis if serum ferritin > 1000 ng/mL or symptoms are present, weekly routine phlebotomy of 1-2 units of blood is performed to reduce serum ferritin < 50 ng/mL and transferrin saturation < 30%, followed by a lifelong maintenance phase with a target serum ferritin < 100 ng/mL and transferrin saturation < 50%. In other cases, when iron-overloaded patients develop anemia, iron chelation is used to remove excess iron from the body [5, 25, 26, 27].

The main iron chelators as standards are deferoxamine (DFO), deferiprone (DFP) and deferasirox (DFX). DFO drugs bind to NTBI or to ferritin forming molecules that are excreted through the kidneys, DFO also promotes ferritin degradation in lysosomes. DFP and DFX drugs perform cytosolic chelation of labile iron. In addition, DFX can increase hepsidin levels resulting in ferroportin degradation. Differences among the three drugs include route of administration, pharmacokinetic profile and side effects. DFO drug has a half-life of 30 minutes and is administered subcutaneously or intravenously at a dose of 20-40 mg/kg/day for 8-24 hours for 5-7 days per week. DFO can also be administered by intravenous continuous infusion at a dose of 40-50 mg/kg/day for 8-12 hours. Therapy with DFO is usually combined with DFP in patients with severe iron overload due to heart failure. DFP and DFX are oral chelates with longer half-lives of 2-3 hours and 8-16 hours, respectively. Deferiprone is given at an initial dose of 25 mg/kgBB for 3 doses per day. DFX can be started at an initial dose of 20 mg/kg/day and adjusted based on response up to 30-40 mg/kg/day. Important side effects are local reactions at the infusion site for DFO, agranulocytosis for DFP, and decreased renal function for DFX [5, 25, 26, 27, 28].

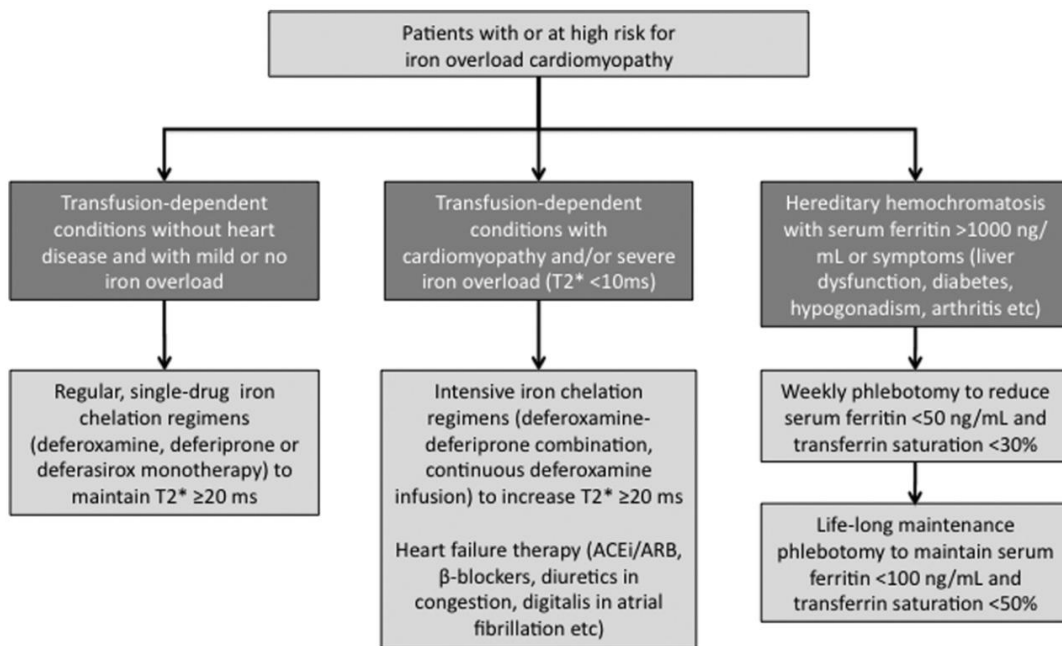


**Figure 3.** Mechanism action of chelating agent

The study of Chapchap et al (2023) showed that iron deposits usually occur first in the liver then pancreas and finally the heart. Administration of iron chelation was shown to significantly reduce cardiac siderosis in thalassemia patients. Evidence suggests that iron chelation improves cardiac function, prevents arrhythmias and reduces mortality in secondary iron overload patients, especially transfusion dependent thalassemia (TDT) patients. Previous studies have shown decreased cardiac morbidity, mortality and reduced cardiac iron deposits in patients treated with DFP when compared to DFO. DFP therapy was also shown to be more effective than DFX in reducing cardiac iron deposits and improving cardiac function [3, 14, 25, 26, 29].

Although the total iron excretion achieved by DFP was reported to be less than that of DFO and DFX, DFP had a more significant cardioprotective effect due to its ability to cross cell membranes. Although each of these three chelates generally reduces cardiac iron deposits and improves ventricular function, this is not achieved in some patients receiving a single iron chelation. Therefore, various combinations of iron chelation have been commonly used to treat patients with iron overload (especially in TDT) with left ventricular dysfunction. The Chuang et al (2020) study stated that compared to DFO alone, the combination of DFO with DFP has been shown to further reduce cardiac siderosis and improve ventricular and endothelial function. However, there are still few clinical studies examining the cardioprotective efficacy of other chelation combination regimens (DFO plus DFX or DFP plus DFX) [3, 14, 25, 26, 29].

In patients with thalassemia major, iron chelation therapy is usually initiated 2-3 years after transfusion initiation and in transfusion dependent patients with MDS or other acquired hematological conditions, iron chelation therapy is usually initiated after 10 to 20 transfusions or about 3-5 liters or started if blood serum ferritin levels have reached 1000 ng/mL or transferrin saturation >70%. In this context, the role of T2\* relaxometry is important in determining therapy. Patients with severe cardiac siderosis ( $T2^* < 10$  ms) with LV remodeling and decreased LVEF or clinical manifestations of heart failure, require intensive therapy, usually with a combination of DFO and DFP or if clinically unstable continuous infusion of deferoxamine can be given to increase  $T2^* > 20$  ms and improve cardiac performance. Patients with  $T2^* 10-19$  ms with low to moderate cardiac symptoms and no evidence of IOC are treated with a single iron chelation regimen to increase  $T2^* > 20$  ms with close follow-up. Although combination iron chelation therapy can be considered in patients with  $T2^* 10-15$  ms. Patients without cardiac siderosis ( $T2^* > 20$  ms) and no evidence of IOC are treated with a single regimen to maintain  $T2^* > 20$  ms. Patients with MDS are treated with a single iron chelation regimen and DFX is an option due to its simple dosing, superior efficacy and milder side effects [5, 28, 30].



**Figure 4.** Management of iron overload cardiomyopathy

Several studies have observed that iron uptake into the heart (and other excitable tissues) occurs through calcium channels, especially LTCC and TTCC. This is the basis for the use of calcium channel blockers (CCBs), such as amlodipine and verapamil. Studies suggest that there is a decrease in iron accumulation in the heart and can prevent heart disease in mice with iron overload. Verapamil treatment reduced cardiac iron levels in hemojuvelin knockout (KO) mice. Several case reports have shown that CCBs have therapeutic effects in patients with secondary iron overload. In vitro and ex vivo studies, efonidipine (TTCC blocker) or verapamil and amlodipine (LTCC blocker) can prevent iron uptake into cardiomyocytes. Several rodent models of thalassemia with iron overload, treatment with LTCC blockers (amlodipine, nifedipine, and verapamil) or TTCC blockers (efonidipine) resulted in a significant reduction in Fe<sup>2+</sup> uptake, reduced cardiac iron deposition and improved cardiac mitochondrial function. All findings suggest that LTCC and TTCC blockers may exert cardioprotective effects under conditions of iron overload. Early phase I clinical studies with amlodipine showed positive results in patients with thalassemia major and phase II trials demonstrated the therapeutic effect of amlodipine as an adjunct to standard therapy of patients with secondary iron overload. Amlodipine as an inhibitor of Fe<sup>2+</sup> influx mediated by LTCC and an anti-oxidant that reduces oxidative stress. Amlodipine's ability to balance between ventricular LTCC blockade and avoid excessive blockade of the sinoatrial node (SA node) and atrio-ventricular node (AV node) can exacerbate bradyarrhythmias. An additional benefit of amlodipine as an LTCC inhibitor is that it can promote vascular relaxation, thereby improving myocardial microvascular perfusion. In addition, amlodipine is also an anti-oxidant and plays an important role to reduce oxidative stress in iron overload cardiomyopathy so amlodipine may have therapeutic benefits independent of cardiac LTCC inhibition alone [2, 7, 8, 9, 10, 14].

Results from clinical studies support preclinical data showing that the combination of iron chelation and amlodipine results in reduced cardiac iron levels, as verified by T<sub>2</sub>\* cardiac MRI. Although the use of CCBs is limited to patients with advanced systolic dysfunction due to their negative inotropic effect and several side effects including gastrointestinal upset, dizziness and ankle swelling. Furthermore, although TTCC blockers have shown cardioprotective effects in experimental animals against iron-induced cardiotoxicity, further clinical studies are needed to confirm these effects in humans [11, 14].

The study of Das et al (2018) showed that resveratrol antioxidant therapy in hemojuvelin knockout male mice as a model of IOC, showed significant improvement in heart function. Echocardiography showed complete improvement in diastolic and systolic dysfunction. Iron-mediated oxidative stress and myocardial fibrosis were suppressed by resveratrol treatment with concomitant activation of the p-Akt and p-AMP-activated protein kinase (AMPK) signaling pathways. This therapy suggests that resveratrol is a feasible therapeutic intervention to reduce the burden on IOC [12].

#### 4. Conclusion

Excessive accumulation of iron in cardiomyocytes called iron overload cardiomyopathy caused by abnormal iron absorption or repeated blood transfusions. The diagnosis of iron overload cardiomyopathy include evidence of heart disease, especially LV diastolic dysfunction with restrictive filling or LV remodeling with dilatation of the heart chambers and decreased left ventricular ejection fraction, the presence of iron overload (serum ferritin > 300 ng/mL and transferrin saturation > 55%) and cardiac siderosis with cardiac T2\*MRI < 20 ms. Cardiac T2\*MRI is the gold standard in quantitative assessment of cardiac iron deposits. Management of iron overload cardiomyopathy by lowering systemic iron levels or preventing iron entry into tissues. Phlebotomy and iron chelation therapy are performed according to indications. Administration of calcium channel blockers and resveratrol can be considered as adjunctive therapy in patients treated with iron chelation.

#### 5. Data Availability Statement

The datasets generated and analyzed during the current study are not publicly available due to privacy and ethical considerations but are available from the corresponding author upon reasonable request.

#### 6. Ethical Statement

Sumatera Medical Journal (SUMEJ) is a peer-reviewed electronic international journal. This statement clarifies ethical behavior of all parties involved in the act of publishing an article in Sumatera Medical Journal (SUMEJ), including the authors, the chief editor, the Editorial Board, the peer-reviewer and the publisher (TALENTA Publisher Universitas Sumatera Utara). This statement is based on COPE's Best Practice Guidelines for Journal Editors.

#### 7. Author Contributions

All authors contributed to the analysis and finalizing the manuscript.

#### 5. Funding

No funding.

#### 6. Acknowledgements

The authors would like to express their sincere gratitude to the staff of this study for their valuable assistance during data collection and analysis.

#### 7. Conflict of Interest

Authors declares no conflict of interest.

#### References

- [1] Aydinok Y, et al. Prevalence and distribution of iron overload in patients with transfusion-dependent anemias differs across geographic regions: Results from the CORDELIA study. *Eur J Haematol*. 2015;95(3):244–53. Available from: <https://doi.org/10.1111/ejh.12487>.
- [2] Zhang H, Zhabyeyev P, Wang S, Oudit GY. Role of iron metabolism in heart failure: From iron deficiency to iron overload. *Biochim Biophys Acta Mol Basis Dis*. 2019;1865(7):1925–37. Available from: <https://doi.org/10.1016/j.bbadis.2018.08.030>.
- [3] Chapchap EC, et al. Cardiac iron overload evaluation in thalassaemic patients using T2\* magnetic resonance imaging following chelation therapy: a multicentre cross-sectional study. *Hematol Transfus Cell Ther*. 2023;45(1):7–15. Available from: <https://doi.org/10.1016/j.htct.2021.01.014>.
- [4] Albakri A. Iron overload cardiomyopathy: A review of literature on clinical status and meta-analysis of diagnostic and clinical management using iron chelators. *Internal Medicine and Care*. 2018;2(1):1–10. Available from: <https://doi.org/10.15761/imc.1000117>.
- [5] Kremastinos DT, Farmakis D. Iron overload cardiomyopathy in clinical practice. *Circulation*. 2011. Available from: <https://doi.org/10.1161/CIRCULATIONAHA.111.050773>.
- [6] McDonagh TA, et al. 2021 ESC Guidelines for the diagnosis and treatment of acute and chronic heart failure. 2021. Oxford University Press. Available from: <https://doi.org/10.1093/eurheartj/ehab368>.
- [7] Fernandes JL, et al. Amlodipine reduces cardiac iron overload in patients with thalassemia major: A pilot trial. *Am J Med*. 2013;126(9):834–7. Available from: <https://doi.org/10.1016/j.amjmed.2013.05.002>.
- [8] Oudit GY, Backx PH. Amlodipine therapy for iron-overload cardiomyopathy: The enduring value of translational research. *Pulsus Group Inc*. 2016. Available from: <https://doi.org/10.1016/j.cjca.2015.11.017>.

- [9] Zhabyeyev P, Sadasivan C, Shah S, Wang F, Oudit GY. Amlodipine rescues advanced iron overload cardiomyopathy in hemojuvelin knockout murine model: Clinical implications. *Front Cardiovasc Med*. 2023;10:1129349. Available from: <https://doi.org/10.3389/fcvm.2023.1129349>.
- [10] Fernandes JL, et al. A randomized trial of amlodipine in addition to standard chelation therapy in patients with thalassemia major. *Blood*. 2016;128(12):1555–61. Available from: <https://doi.org/10.1182/blood-2016-06-721183>.
- [11] Khaled A, Salem HA, Ezzat DA, Seif HM, Rabee H. A randomized controlled trial evaluating the effects of amlodipine on myocardial iron deposition in pediatric patients with thalassemia major. *Drug Des Devel Ther*. 2019;13:2427–36. Available from: <https://doi.org/10.2147/DDDT.S211630>.
- [12] Das SK, et al. Advanced iron-overload cardiomyopathy in a genetic murine model is rescued by resveratrol therapy. *Biosci Rep*. 2018;38(1):BSR20171302. Available from: <https://doi.org/10.1042/BSR20171302>.
- [13] Paterek A, Mackiewicz U, Mączewski M. Iron and the heart: A paradigm shift from systemic to cardiomyocyte abnormalities. *Wiley-Liss Inc*. 2019. Available from: <https://doi.org/10.1002/jcp.28820>.
- [14] Kumfu S, Chattipakorn SC, Chattipakorn N. Iron overload cardiomyopathy: Using the latest evidence to inform future applications. *SAGE Publications Inc*. 2022. Available from: <https://doi.org/10.1177/15353702221076397>.
- [15] Kumfu S, Siri-Angkul N, Chattipakorn SC, Chattipakorn N. Silencing of lipocalin-2 improves cardiomyocyte viability under iron overload conditions via decreasing mitochondrial dysfunction and apoptosis. *J Cell Physiol*. 2021;236(7):5108–20. Available from: <https://doi.org/10.1002/jcp.30219>.
- [16] Sumneang N, Siri-Angkul N, Kumfu S, Chattipakorn SC, Chattipakorn N. The effects of iron overload on mitochondrial function, mitochondrial dynamics, and ferroptosis in cardiomyocytes. *Academic Press Inc*. 2020. Available from: <https://doi.org/10.1016/j.abb.2019.108241>.
- [17] Zimmerman MJ, Rosing DR, Shizukuda Y. Advancement of echocardiography for surveillance of iron overload cardiomyopathy: comparison to cardiac magnetic resonance imaging. *Springer Japan*. 2021. Available from: <https://doi.org/10.1007/s12574-021-00524-x>.
- [18] Carpenter JP, et al. On T2\* magnetic resonance and cardiac iron. *Circulation*. 2011;123(14):1519–28. Available from: <https://doi.org/10.1161/CIRCULATIONAHA.110.007641>.
- [19] Yang G, Liu R, Peng P, Long L, Zhang X, Yang W, et al. How early can myocardial iron overload occur in beta thalassemia major? *Plos One*. 2014. Available from: <https://doi.org/10.1371/journal.pone.0103199>.
- [20] Atmakusuma TD, Kalwani R, Nasution SA, Rumende M. Correlation of serum ferritin and cardiac iron toxicity with cardiac function in transfusion dependent beta-thalassemia major patients. *J Thalassemia*. 2021.
- [21] Wahidiyat PA, Iskandar SD, Sekarsari D, Wahidiyat PA. Evaluation of iron overload between age groups using magnetic resonance imaging and its correlation with iron profile in transfusion-dependent thalassemia. *J Hematol Ther*. 2018.
- [22] Eghbali A, Mehrabi S, Ghandi Y, Eghbali A, Dabiri M, Mousavi-Hasanzadeh M. Serum markers and cardiac T2\* MRI in thalassemia major. The correlation between serum ferritin, serum troponin T, cardiac T2\* MRI, and echocardiographic findings in patients with thalassemia major. *Int J Blood Cancer*. 2020. Available from: [www.ijbc.ir](http://www.ijbc.ir).
- [23] Heris HK, et al. Evaluation of iron overload by cardiac and liver T2\* in  $\beta$ -thalassemia: Correlation with serum ferritin, heart function, and liver enzymes. *J Cardiovasc Thorac Res*. 2021;13(1):54–60. Available from: <https://doi.org/10.34172/jcvtr.2021.18>.
- [24] Darvishi-Khezri H, et al. Ferritin thresholds for cardiac and liver hemosiderosis in  $\beta$ -thalassemia patients: a diagnostic accuracy study. *Sci Rep*. 2022;12(1):22234. Available from: <https://doi.org/10.1038/s41598-022-22234-9>.
- [25] Bruzzese A, et al. Iron chelation therapy. *John Wiley and Sons Inc*. 2023. Available from: <https://doi.org/10.1111/ejh.13935>.
- [26] Entezari S, et al. Iron chelators in treatment of iron overload. *Hindawi Limited*. 2022. Available from: <https://doi.org/10.1155/2022/4911205>.
- [27] Origa R, et al. Safety and efficacy of the new combination iron chelation regimens in patients with transfusion-dependent thalassemia and severe iron overload. *J Clin Med*. 2022;11(7):2010. Available from: <https://doi.org/10.3390/jcm11072010>.
- [28] Faheri E, Hidayat R, et al. Update in diagnostic procedure and treatment in internal medicine: Towards evidence-based competency. *Kumpulan Makalah Pertemuan Ilmiah Nasional ke XIX Perhimpunan Dokter Spesialis Penyakit Dalam Indonesia*. 2021.

- [29] Chuang TY, Li JP, Weng TF, Wu KH, Chao YH. Combined chelation with high-dose deferiprone and deferoxamine to improve survival and restore cardiac function effectively in patients with transfusion-dependent thalassemia presenting severe cardiac complications. *Ann Hematol.* 2020;99(10):2289–94. Available from: <https://doi.org/10.1007/s00277-020-04196-y>.
- [30] Vinchi F, Hell S, Platzbecker U. Controversies on the consequences of iron overload and chelation in MDS. *Hemasphere.* 2020;4(3). Available from: <https://doi.org/10.1097/HS9.0000000000000357>.