



Case Report

Case Report: Masson's Tumor in Maxillary Sinus with Concurrent Inferior Turbinate Hemangioma, a Rare Entity

Manpreet Kaur Kuldep Singh^{*1}, Revadi Govindaraju²

¹Department of Psychological Medicine, Faculty of Medicine, Universiti Malaya, Kuala Lumpur, 50603, Malaysia

²Associate Professor, Consultant Otorhinolaryngologist (ENT), Universiti Malaya, Kuala Lumpur, 50603, Malaysia

*Corresponding Author: manpreet2104@yahoo.com

ARTICLE INFO

Article history:

Received 29 September 2024

Revised 18 December 2024

Accepted 26 December 2024

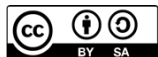Available online 1 January 2025

E-ISSN: 2622-1357

P-ISSN: 2622-9234

How to cite:

Manpreet Kaur Kuldep Singh, Revadi Govindaraju, "Case Report: Masson's Tumor in Maxillary Sinus with Concurrent Inferior Turbinate Hemangioma, a Rare Entity", SUMEJ, Vol. 08, No. 01, January 2025.



This work is licensed under a Creative Commons Attribution-ShareAlike 4.0 International. <https://doi.org/10.32734/sumej.v8i1.18313>

ABSTRACT

Background: Masson's tumour, also known as intravascular papillary endothelial hyperplasia (IPEH), is a relatively uncommon benign vascular lesion that develops in organising thrombus, whereas hemangiomas are benign vascular tumours that can develop anywhere there are blood vessels. **Objective:** To report a rare case of Masson's tumour in the maxillary sinus with concurrent inferior turbinate hemangioma and to explore the possible association between these two vascular anomalies. **Methods:** A 31-year-old female patient who is otherwise healthy presented with intermittent epistaxis, facial pain, and numbness. Imaging examinations discovered a mass in the maxillary sinus, which led to a possible malignancy diagnosis. **Results:** A post-surgery histological report supported the diagnosis of a benign vascular lesion called Masson's tumour in the maxillary sinus with concurrent inferior turbinate hemangioma. Based on our literature review, this is the 12th case of IPEH in the maxillary sinus. **Conclusion:** The concurrent presentation of Masson's tumour in the maxillary sinus with an inferior turbinate hemangioma suggests a possible association between these two vascular anomalies.

Keywords: intravascular papillary endothelial hyperplasia, inferior turbinate, haemangioma, masson tumor, maxillary sinus

1. Introduction

Masson's tumour, also known as intravascular papillary endothelial hyperplasia (IPEH), is a relatively uncommon benign vascular lesion made up of reactive endothelial cell proliferation and papillary forms that develop in organising thrombus. IPEH may initially be mistaken as a malignancy due to overlapping histologic characteristics, such as angiosarcoma or Kaposi's sarcoma [1-4]. Hemangiomas are benign vascular tumours that can develop anywhere there are blood vessels, including the skin, mucous membranes, muscles, glands, and bones. Hemangiomas frequently occur in the head and neck region, but seldom in the nasal cavity. The vestibule (16%), lateral wall (18%), and nasal septum (65%) are the most typical locations for nasal hemangiomas [13, 14]. Here, we report a unique case of IPEH of maxillary sinus with concurrent inferior turbinate hemangioma in a female patient.

2. Case Presentation

A 31-year-old female patient who was otherwise healthy, was referred to our Otorhinolaryngology, Head and Neck Surgery clinic for right maxillary sinus and inferior turbinate hemangioma on MRI Paranasal sinus and histopathological examination following history of repeated episodes of unprovoked epistaxis since November 2020.

She was previously treated in another tertiary hospital, where a CECT Paranasal sinus was initially done which revealed right maxillary sinus soft tissue mass with extension to infratemporal fossa and erosion of posterior maxillary wall with heterogenous enhancement. The referring team subsequently proceeded with right inferior turbinectomy (anterior part), right inferior meatal anastomosis and biopsy of right maxillary sinus mass. The intraoperative histopathologic examination showed features that favour hemangioma.

Upon review in our clinic, she still complained of daily blood-stained rhinorrhea. She otherwise denies nasal blockage, facial pain, headache or visual disturbances. Endoscopic examination revealed evidence of right anterior meatotomy with inferior turbinectomy. A mass was seen in the right maxillary sinus with blood-stained mucoid discharge at the right nasal vestibule.

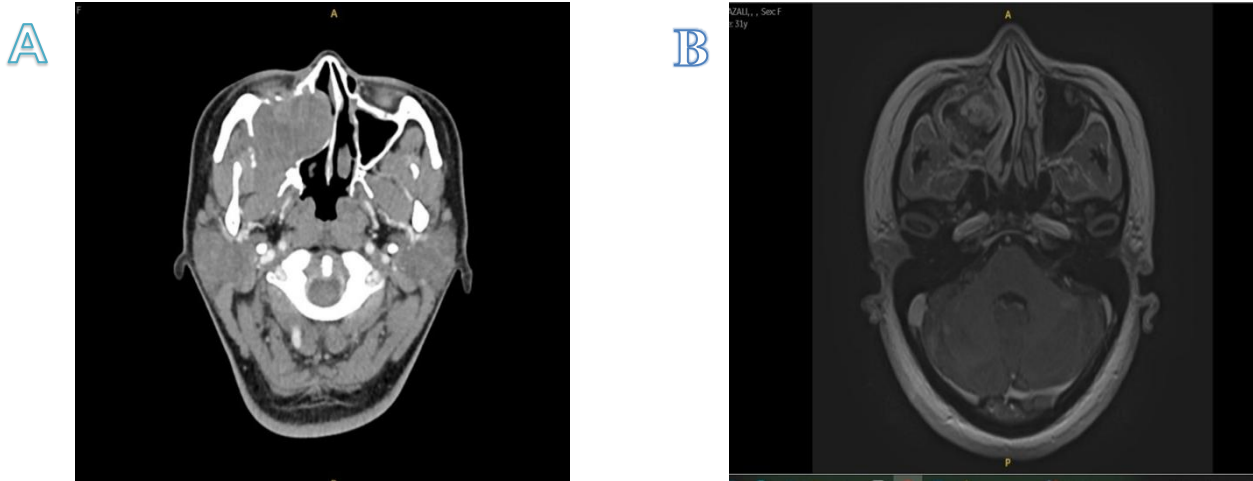


Figure 1. (a) Axial CT Scan Image showing expansile mass in right maxillary sinus with erosion of the surrounding wall; (b) Axial MRI image showing expanded right maxillary sinus with heterogeneously enhancing lobulated soft tissue lesion

The Computerized tomography (CT) imaging prior to biopsy revealed a heterogeneously enhancing expansile mass in the right maxillary sinus, measuring approximately 4.3 x 4.9 x 3.6 cm (AP x W X CC). It is associated with remodeling and erosion of the surrounding wall. Medially, the mass extended into the nasal cavity. Laterally, the mass extended into the right buccal, masticator and infratemporal spaces. Superiorly, the mass extended into the right ethmoid sinus and causing erosion of the left orbital floor. The Magnetic Resonance Imaging (MRI) done post biopsy revealed an expanded and heterogeneously enhancing lobulated soft tissue lesion measuring 2.3 x 3.2 x 2.7 cm (AP x W x CC) in the right maxillary sinus. It was isointense to muscle on T1WI, mixed hypointense and hyperintense signal on T2WI.

The patient underwent excision of sinonasal mass via endoscopic right medial maxillectomy under general anaesthesia. Tissue samples were taken from right maxillary sinus and posterior stump of inferior turbinate. Diagnosis of Maxillary sinus IPEH and inferior turbinate hemangioma of the cavernous type was confirmed by postoperative histological examination. The tissue sample from the maxillary sinus microscopically appeared as inflamed fibro-connective tissue, focally covered by benign respiratory type epithelium, composed of large areas of fibrin and scattered papillae lined by single layered endothelial cells. No granulomas, fungal bodies (GMS is negative), dysplasia or malignant cells seen. The tissue sample from the posterior stump of inferior turbinate revealed fibro-connective tissue covered by benign respiratory-typed epithelium exhibiting proliferation of dilated and some anastomosing thin-walled vessels lined by benign flattened endothelial cells (as highlighted by EVG). Post-operatively, the patient recovered smoothly, with her symptoms resolving. During her follow-up clinic visit, no signs of recurrence were observed.

In a literature review of 314 cases of IPEH, it revealed that 56% of cases were primary type, 40% secondary type, and 4% were an extravascular type. The secondary type was believed to have arose from a pre-existing vascular anomaly such cavernous hemangiomas, arteriovenous malformations, lymphangiomas and vascular hamartomas [1,3,4]. Based on our literature review, despite the large number of cases occurring in the head & neck region, only 11 cases were reported in the paranasal sinus?? to prior to our case [1-4,6,8-11]. A summary of the literature review can be found in Table:

Table 1. Literature review of reported cases of IPEH involving maxillary sinus

Cases	Sex/Age	Localization	Symptoms	Imaging	Treatment	Recurrence
Stern (1991) ^[8]	M/17	Right maxillary sinus, ethmoid and nasal cavity	Frontal headaches, cheek pain, exophthalmos	CT	Caldwell-luc Excision	No
Lancaster (1998) ^[9]	F/67	Left maxillary sinus and ethmoid	Nasal obstruction, rhinorrhea	CT	Endoscopic Excision	No
Wang (2009) ^[10]	M/42	Left maxillary sinus, ethmoid, frontal sinus, and nasal cavity	Nasal obstruction, rhinorrhea, epistaxis, frontal headaches	CT + MRI	Endoscopic Excision	No
Tuna (2015) ^[11]	M/58	Left ethmoid, sphenoid, maxillary sinus, nasal cavity, choana, pterygopalatine fossa and orbit	Nasal obstruction, epistaxis, exophthalmos	CT + MRI	Lateral rhinotomy incision	N/A
Al-Qahtani (2016) ^[6]	F/33	Right nasal cavity, maxillary, ethmoid, frontal, sphenoid sinus.	Nasal obstruction, epistaxis, rhinorrhea, anosmia, frontal headaches, exophthalmos	CT	Endoscopic Excision	No
Anez EM (2016) ^[4]	M/20	Right maxillary sinus, nasal cavity	nasal obstruction, rhinorrhea, frontal headache and pressure sensation	CT	Combined Caldwell-Luc and endoscopic excision	No
D'Aguanno (2018) ^[3]	F/67	Right Maxillary Sinus	Right cheek pain, rhinorrhea, postnasal discharge	CT + MRI	Combined Caldwell-Luc and endoscopic excision	No
Peter Cooke (2019) ^[1]	M/28	Right Maxillary Sinus, Bilateral nasal cavity, Bilateral ethmoid	Bilateral nasal obstruction, epistaxis, headaches, Right cheek pain, itchy eye	CT	Endoscopic excision	No
François Voruz (2020) ^[2]	M/46	Left maxillary sinus	Nasal obstruction, bloody-serous rhinorrhea	CT	Endoscopic excision	No

François Voruz (2020) ^[2]	M/76	Right maxillary sinus and nasal cavity	Epistaxis, rhinorrhea	CT + MRI	Endoscopic excision	No
François Voruz (2020) ^[2]	F/33	Right maxillary sinus	Rhinorrhea, orbital pressure, headaches	CT + MRI	Endoscopic excision	No
Present case (2023)	F/31	Right maxillary sinus, nasal cavity, ethmoid sinus, infratemporal space, buccal space, massitor space	Epistaxis, facila pain and numbness	CT + MRI	Endoscopic excision	No

3. Discussion

Hemangio-endotheliome vegetant intravasculaire was the term coined by French pathologist Pierre Masson in 1923 to characterise an endothelial hyperplasia with papillary histologic characteristics. Currently, the term most frequently used to describe it is intravascular papillary endothelial hyperplasia (IPEH), which was first used by Clearkin et al. According to how they affect a vessel, three different types of papillary endothelial hyperplasia are documented in the literature. The primary type develops in a dilated vessel's lumen [1]. The second develops in a preexisting vascular neoplasm, such as a hemangioma, pyogenic granuloma, or arteriovenous malformation. A papillary hyperplasia of extravascular origin is the third and rarest IPEH variation [5]. In the present case, we considered it was the secondary type as the initial biopsy favoured hemangioma to suggest a pre-existing vascular anomaly.

The differential diagnosis of IPEH is challenging as it has been clinically mistaken most commonly for angiosarcoma due to its resemblance to it [2, 6]. Histopathologically, there are a few significant distinguishing characteristics that are helpful in excluding an angiosarcoma diagnosis: i) IPEH resides intravascular, whereas angiosarcomas penetrate the tissue around them ii) The majority of the papillary structures have thrombi attached to them iii) almost rarely associated with necrosis iv) lack of mitotic figures and pleomorphism of the cells [1-7]. Immunohistochemically, IPEH usually stains positively for CD31, CD34, and smooth muscle actin (SMA) [3, 4, 6]. In the present case, immunohistochemistry was not performed as there was no diagnostic dilemma and features suggestive of IPEH.

Radiologically, the characteristic features are usually unspecific and difficult to diagnose IPEH. On CT Paranasal sinus, IPEH usually appears as an expansile mass with tendency to erode the surrounding bone, similar to metastatic tumor. On MRI, when gadolinium is injected, MRI T2-weighted scans may reveal a hyperintense mass with numerous septa and a peripheral rim that is hypointense, as well as strong and heterogeneous enhancement. An isointense to slightly hypo-intense mass is shown on T1 weighted images, with some hyperintense patches inside the mass compartment [3, 4].

For IPEH, a number of surgical strategies have been suggested for complete surgical removal or excision of lesion. A few studies have described endoscopic management as well as an open approach using the Caldwell-Luc method or a Weber-Ferguson incision. Both methods act as both diagnostic and therapeutic methods [3]. The prognosis is excellent as IPEH does not show malignancy transformation nor recur after adequate excision [1, 6]. Therefore, complete surgical removal is the most common treatment [1].

4. Conclusion

Although benign, IPEH is clinically significant as it presents as a mass lesion that is frequently misdiagnosed on radiological imaging and may be histologically confused with angiosarcoma. Complete surgical excision results in a cure, making accurate diagnosis crucial to prevent unnecessary additional treatments.

5. Data Availability Statement

The datasets generated and analyzed during the current study are not publicly available due to privacy and ethical considerations but are available from the corresponding author upon reasonable request.

6. Ethical Statement

Sumatera Medical Journal (SUMEJ) is a peer-reviewed electronic international journal. This statement below clarifies ethical behavior of all parties involved in the act of publishing an article in Sumatera Medical Journal (SUMEJ), including the authors, the chief editor, the Editorial Board, the peer-reviewer and the publisher (TALENTA Publisher Universitas Sumatera Utara). This statement is based on COPE's Best Practice Guidelines for Journal Editors

7. Author Contributions

All authors contributed to the design and implementation of the research, data analysis, and finalizing the manuscript.

8. Funding

No funding.

9. Acknowledgements

The authors would like to thank the Department of Otorhinolaryngology, Universiti Malaya, for the support provided throughout the diagnostic and surgical management of this case. We are also grateful to the pathology team for their expertise in establishing the histological diagnosis. Our sincere appreciation goes to the patient for her cooperation and consent in allowing this rare and informative case to be shared with the medical community.

10. Conflict of Interest

Authors declares no conflict of interest.

References

- [1] Cooke P, Goldrich D, Iloreta AM, Salama A, Shrivastava R. Intravascular papillary endothelial hyperplasia of the maxillary sinus in patient with tricuspid atresia. *Head Neck Pathol.* 2020 Sep;14(3):803-7. Available from: <https://doi.org/10.1007/s12105-019-01070-w>.
- [2] Voruz F, Arnoux G, Serex CA, de Vito C, Landis BN. Intravascular papillary endothelial hyperplasia (Masson's tumor) of maxillary sinus. *Braz J Otorhinolaryngol.* 2022 Jan-Feb;88(1):141-5. Available from: <https://doi.org/10.1016/j.bjorl.2020.11.007>.
- [3] D'Aguanno V, Ralli M, De Virgilio A, Greco A, de Vincentiis M. The role of differential diagnosis in intravascular papillary endothelial hyperplasia of the sinonasal cavity mimicking angiosarcoma: a case report. *Oncol Lett.* 2018. Available from: <https://doi.org/10.3892/ol.2018.9717>.
- [4] Anez EM, Beilke RP, Cavada MN, Martha AS. Masson's tumor in the maxillary sinus. *J Otolaryngol ENT Res.* 2016;4(5):00115. Available from: <https://doi.org/10.15406/joentr.2016.04.00115>.
- [5] Hashimoto H, Daimaru Y, Enjoji M. Intravascular papillary endothelial hyperplasia: a clinicopathologic study of 91 cases. *Am J Dermatopathol.* 1983 Dec;5(6):539-46. Available from: <https://doi.org/10.1097/00000372-198312000-00004>.
- [6] Al-Qahtani KH. Intravascular papillary endothelial hyperplasia (Masson's tumor) as a nasal mass: a case report and review of the literature. *Pan Arab J Rhinol.* 2016;6:33-5.
- [7] Akdur P, Akdur O, Duran C, et al. Intravascular papillary endothelial hyperplasia: histomorphological and immunohistochemical features. *Diagn Pathol.* 2013;8:167. Available from: <https://doi.org/10.1186/1746-1596-8-167>.
- [8] Stern Y, Braslavsky D, Segal K, Shpitzer Y, Abraham A. Intravascular papillary endothelial hyperplasia in the maxillary sinus. A benign lesion that may be mistaken for angiosarcoma. *Arch Otolaryngol Head Neck Surg.* 1991;117(11):1182-4.
- [9] Lancaster JL, Alderson DJ, Sherman IW, Clark AH. Papillary endothelial hyperplasia (Masson's tumour) of the maxillary sinus. *J Laryngol Otol.* 1998 Jul;112(7):500-2.
- [10] Wang ZH, Hsin CH, Chen SY, Lo CY, Cheng PW. Sinonasal intravascular papillary endothelial hyperplasia successfully treated by endoscopic excision: a case report and review of the literature. *Auris Nasus Larynx.* 2009 Sep;36(3):363-6.
- [11] Tuna EEÜ, Türkay B, Kurukahvecioğlu S, Ataoğlu Ö, Eryılmaz A. Sinonasal intravascular papillary endothelial hyperplasia (Masson's tumor). *ENT Case.* 2015.
- [12] Akiner MN, Akturk MT, Demirtas M, Atmis EO. Intraosseous cavernous hemangioma of inferior turbinate: a rare case report. *Case Rep Otolaryngol.* 2011;2011:431365. Available from: <https://doi.org/10.1155/2011/431365>.

- [13] Goff R, Weindling S, Gupta V, Nassar A. Intraosseous hemangioma of the middle turbinate: a case report of a rare entity and literature review. *Neuroradiol J.* 2015 Apr;28(2):148-51. Available from: <https://doi.org/10.1177/1971400915576653>.
- [14] Stubbs D, Poullos A, Khalil H. Benign sinonasal capillary haemangioma. *BMJ Case Rep.* 2014 Oct 6;2014:bcr2014207070. Available from: <https://doi.org/10.1136/bcr-2014-207070>.