

Case Report

Laminectomy Decompression in Radiculopathy Vertebrae L3-L4, L4-L5: A Case Report

Radityo Priambodo*, Sevline Estethia Ompusunggu, Rully Hanafi Dahlan

Division of Spine Surgery, Department of Neurosurgery, Hasan Sadikin Hospital, Padjadjaran University, Bandung, 45363, Indonesia

Abstract

Background: Spinal tumors are uncommon lesions and affect only a minority of the population. Spinal metastases comprise approximately 97% of masses encountered with spinal imaging and are the most common site of metastasis from breast cancer. The signs and symptoms for metastatic spinal tumors vary from back pain, motoric and sensoric dysfunction, and in advanced disease, spinal cord compression. **Objective:** To report a case of metastatic spinal tumor in a patient with a history of breast cancer presenting with lower limb weakness. **Methods:** A 39-year-old female patient with complaints of lower limb weakness and a history of breast cancer underwent a contrast lumbosacral MRI examination, revealing metastatic spine tumors. The patient was planned for laminectomy decompression, tumor resection, and posterior stabilization procedures. **Results:** The MRI confirmed the presence of metastatic spinal tumors. The patient underwent planned surgical interventions including laminectomy decompression, tumor resection, and posterior stabilization. **Conclusion:** Spinal tumors are conditions that can arise within the spinal cord itself or from adjacent structures and affect only a minority of the population. The hallmark symptom for spinal metastases is back pain. Surgical techniques such as open decompression and stabilization are used based on the patient's condition, particularly in cases with neurodeficits and compression seen on radiological examination, and they offer a good prognosis.

Keywords: breast cancer, metastatic spinal tumors, neurosurgery, weakness

Received: 03 August 2023 | Revised: 25 August 2023 | Accepted: 9 September 2023

1. Introduction

Spinal tumors are uncommon lesions and affect only a minority of the population. Spine tumors can arise within the spinal cord itself, or from the adjacent structures. However, these lesions can cause significant morbidity as well. In general, extradural lesions are most common spinal tumors where most often caused by metastases from distant organ [1]. Spinal metastases comprising approximately 97% of masses encountered with spinal imaging and is the most common site of metastasis from breast cancer [2]. Walkington and Coleman estimated that 70% of women with advanced breast cancer will develop bone metastasis [3].

Spinal metastases may lead to axial pain and functional limitations resultant from pathological vertebral body fractures, and radiculopathy and/or myelopathy from epidural involvement leading to spinal cord or nerve root compression. Approximately 10% of patients with vertebral body metastases will develop spinal cord compression, a severe and potentially permanently disabling complication that requires emergent treatment [4].

With the improvement of surgical technology, the surgeon now can treat spinal metastases more effectively than before. Therefore, we must remember that most patients with metastatic spinal tumors have a life

* Corresponding author at: Division of Spine Surgery, Department of Neurosurgery, Hasan Sadikin Hospital, Padjadjaran University, Bandung, 45363, Indonesia
E-mail address: dr.radityo@gmail.com

expectancy which is governed by the tumor type and staging, and is usually <1–2 years. Then, the surgeon or oncologist must be able to predict life expectancy of the patient. It is accepted that surgery might be considered when a patient has a life expectancy of more than 3 months [5]. In our case, we report a patient with metastatic spinal tumor disease that performed surgery.

2. Case Presentation

A 39-year-old female patient came to a neurosurgery outpatient clinic at Hasan Sadikin hospital with complaints of weakness in the lower limb since 1 year ago. Complaints preceded with weakness of right limb followed with left limb to make it difficult for the patient to walk. The complaint got worse overtime until she couldn't walk since 5 months prior to admission. Complaints of numbness and tingling were also felt in both knees. The patient has a history of urinary and defecation disorders. The patient also had a history of losing weight 10 kg in 2 months. The patient had lumps in the right breast 4 years ago and had undergone mastectomy and chemotherapy with the results of histopathological examination of ductal carcinoma in situ.

From the physical examination, the patient's vital signs were within normal limits. In the lumbosacral there is a deformity without tenderness. On the right mammary there is a surgical scar. Neurological examination revealed the patient had a GCS of 15 in the absence of nuchal rigidity. Pupil round was equal 3mm/3mm with light reflex +/+. Sensory examination revealed hypesthesia at L3 and below. The results of the vegetative examination showed urine and alvy incontinence. Laseque's examination was positive, physiological reflex was positive, and pathological reflex was negative.

On April 20, 2022, the patient underwent a thoracolumbar X-ray examination with the impression that there was no malignancy, burst fracture of the vertebrae L3-L4, L4-L5, lumbar lordosis 41.9° , sacral slope was 40.6° (N: 30-50), pelvic tilt was 40.9° (N: 10-25), and pelvic incidence was 81.5° .

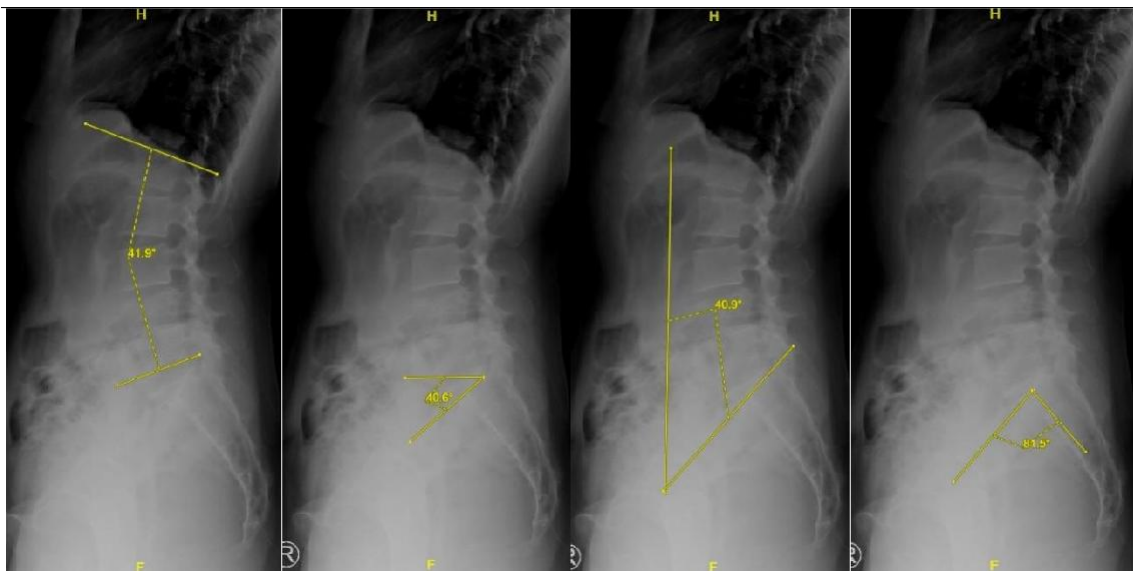


Figure 1. Thoracolumbar X-Ray at Hasan Sadikin Hospital, Bandung April 30th 2022

On June 24, 2022, the patient underwent a contrast lumbosacral MRI examination at Hasan Sadikin hospital. On T1 there was a hypointense lesion at L3-L4, L4-L5 that was enhanced inhomogeneous with contrast administration, pathologic fracture at vertebra level L3-L4, L4-L5, and canal compromise (+). On T2, hyperintense lesions at L3-L4, L4-L5, pathologic fracture at vertebra level L3-L4, L4-L5, and canal compromise (+) were found. The assessment results showed Tomita score was 3 and Tokuhashi score was 12 (Figure 1-2).

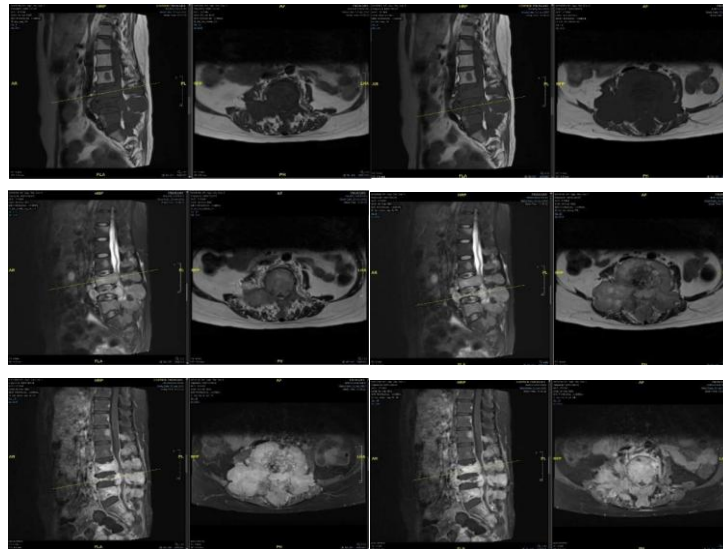


Figure 2. Contrast Lumbosacral MRI at Hasan Sadikin Hospital June 24th 2022.

The patient was then planned to undergo laminectomy decompression, tumor resection, and posterior stabilization procedures. First, the patient is positioned prone and leveling. After that the incision and dissection begin. However, during intraoperative posterior stabilization could not be done because the bone was destroyed so it could not be used as an anchor of screw. Another intraoperative finding is the presence of tumor infiltration from ligaments, paraspinal muscles, spinous processes, and lamina. The patient underwent bilateral laminectomy from L3-L5 (Figure 3-5).

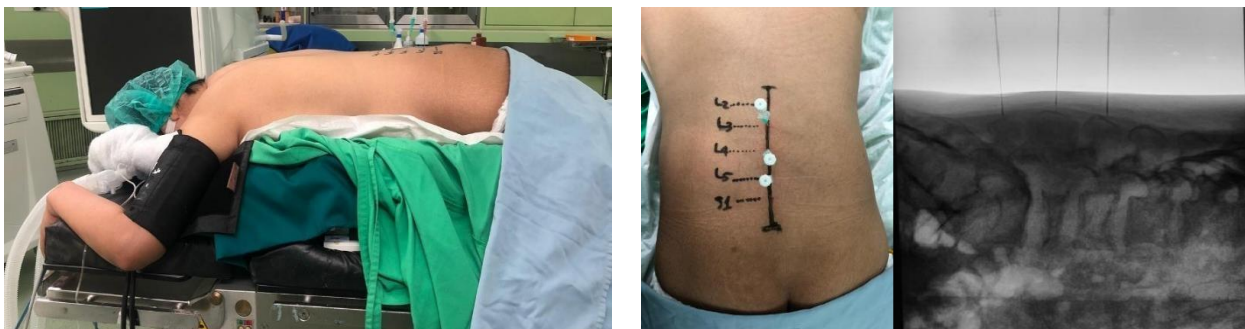

Figure 3. Positioning and Marking

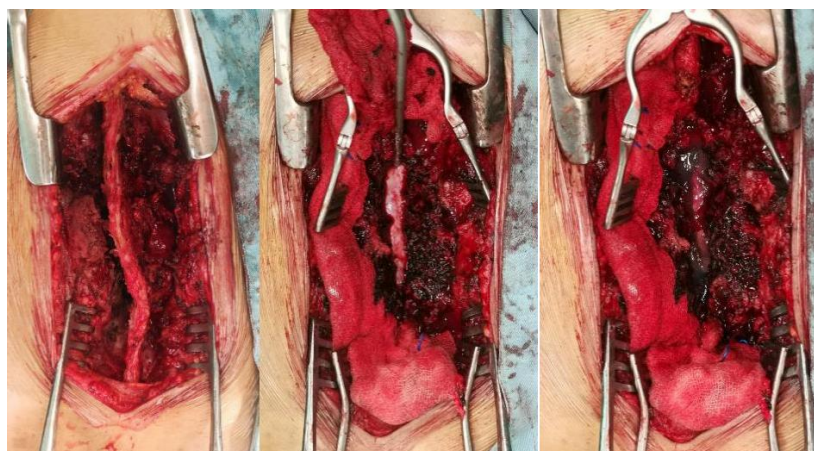


Figure 4. Opening positioning

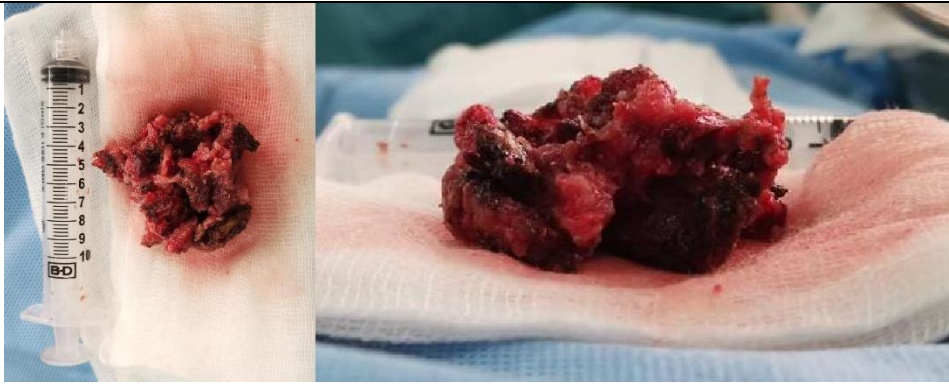

Figure 5. Intraoperative Findings

3. Discussion

According to the World Health Organization, worldwide, breast cancer is one of the most common cancer in women. Specifically, in women, breast cancer is the second leading cause of death after lung cancer. Indonesia is one of the countries with a high incidence of breast cancer. In 2020, breast cancer in women had an incidence of 16.6% and mortality of 9.6% of all cancers in men and women, while specifically in women, breast cancer had the highest incidence, which was 30.8%. Breast cancer was divided into four subtypes identified based on ER and PR excessive or nonexistent, Ki67 protein, and the presence of excessive amplification in HER oncogenes. Four known subtypes are luminal A, luminal B, positive HER2, and Basal-like. The luminal B subtype is found to be around 15-20% of all breast cancer subtypes and has a more aggressive phenotype, with a higher level of malignancy, a proliferation index, and a worse prognosis [6, 7]. About 20% of patients with breast cancer suffer from bone metastases [5-8].

Spine tumors are a diverse group of uncommon neoplasms that develop from tissues in and around the spinal canal. However, these lesions can cause significant morbidity in terms of limb dysfunction and can be associated with mortality [1]. Spine tumors can arise within the spinal cord itself, or from the adjacent structures. These tumors can broadly be divided into primary and secondary (metastatic) tumors. Metastatic spine tumors spread to the vertebral column via hematogenous route (eg, via the Batson plexus). Contrary to primary spine tumors, metastatic spine tumours extremely prevalent (97%). It was found that the percentage of cancer patients who have had bone metastasis before death is between 50% and 70%, and especially in case of breast cancer this percentage rose up to 85% [9].

In general, spine tumors can be classified according to their anatomic location into intradural-intramedullary, intradural-extramedullary, and extradural. Intradural-intramedullary tumors are neoplasms arising within the spinal cord. They account for 20% of all intraspinal tumors in adults and 35% of all intraspinal tumors in children. Most primary intra-axial tumors are either ependymomas or astrocytomas. Tumors are labeled as intradural-intramedullary if the epicenter arises at the level of C1 to the level of the conus (L1/L2). Lesions above C1 and involving the medulla are labeled as cervicomedullary. Intradural-extramedullary tumors are located within the dura but outside the spinal cord. Meningiomas and nerve sheath tumors (NSTs) are the two most common types of tumors. Extradural tumors are the most common (60% of all spine tumors). These tumors arise outside the dural sac, typically from the vertebral bodies. These are usually metastatic in nature [10].

The hallmark symptom for spinal metastases is back pain, with 80% to 95% of patients having this symptom. Pain can be further characterized as local pain, mechanical pain, or radicular pain. Motor dysfunction is the second most common complaint on presentation, present in 35% to 75% of patients. When there is significant neural compression, sensory disturbances can be present and usually accompany pain and/or motor complaints. In its most severe form, metastatic disease can cause spinal cord compression. Although relatively rare, in 10 per 100.000 patients spinal cord compression necessitates emergent evaluation. The symptoms are often advanced and include weakness (60%-85%), sensory disturbances including saddle anesthesia, and bowel/bladder disturbances. Untreated spinal cord compression can progress to paralysis, sensory loss, and bowel/bladder dysfunction [3].

In this case, the patient came with complaints of radiating back pain since six months ago due to metastases from breast cancer in the spinal column. This complaint is exacerbated by metastasis over time so that other complex symptoms begin to appear starting with motor disorders characterized by weakness since five months ago, followed by urinary and defecation disorders due to bowel and bladder dysfunction.

Apart from the basic workup of a patient with the spine tumor, most of the blood and serum studies do not contribute much to the diagnosis in primary tumors of the musculoskeletal system. As part of the workup, imaging studies follow suit. Plain radiographs should be included, as they are easily accessible and allow approximate localization of the disease process (if visible on the radiographs), but also assist in evaluating the curvature of the spine and any changes in its structural appearance secondary to changes in the biomechanics. Once the involved level is identified, CT and MRI are the studies of choice to give much more data on the distribution of the tumor within the vertebrae, its extension, and effects on the local anatomy. MRI with intravenous contrast (Gadolinium) will assist in identifying the areas of most activity, and may direct the placement of the biopsy needle to achieve a high yield. Whole-body technetium-99m bone scan will help identify other sites of involvement, and hence help stage the disease, or even identify another location that may be an easier site for obtaining a piece of tissue for diagnostic purposes [11].

The objective of treatment for metastatic spine tumors is to improve pain relief and anesthesia and to ensure maximum activities of daily living (ADL) and quality of life (QOL) in the short survival period. Actually, the symptoms and survival periods of patients with metastatic spine tumors vary widely, and sufficient consideration of the severity of symptoms and life prognosis is required for determining an effective therapeutic strategy. Accurate evaluation of metastasis and life prognosis before treatment is the most important factor in determining the therapeutic strategy for metastatic spine tumors [12].

The prognosis of metastatic spine tumor varies widely, and it is a major problem for the selection of treatment. Because general condition exerts a greater effect on prognosis than local condition, the evaluation of disease severity or prediction of outcome was difficult by imaging of the local condition. Therefore, Tokuhashi Y (1990,1991) devised a prognostic scoring system consisting of 6 items that are retrospectively considered to affect the outcome (general condition, [Karnofsky performance], number of bone metastases other than spine metastases, number of spine metastases, type of the primary lesion, presence or absence of metastasis to major organs, and state of paralysis) [12-14]. This score was revised in 2005 with the addition of a metastatic score in other organs. Consequently, 6 months and 1 year are used as clinically key periods compared to the previous period, which used 3 months and 1 year [12].

Table 1. Revised Tokuhashi Score (2005)

Predictive Factor	Score (points)
General condition Poor (KPS 10-40%)	0
Moderate (KPS 50-70%)	1
Good (KPS 80-100%)	2
Number of extraspinal bone metastases foci ≥ 3	2
Metastases to the major internal organs	0
Unremovable	1
Removable	2
No metastases	
Primary site of the cancer	0
Lung, osteosarcoma, stomach, bladder, esophagus, pancreas	1
Liver, gallbladder,	2
Unidentified Others	0
Kidney	
Uterus Rectum	1
Thyroid	2
Prostate	3
Breast	4
Carcinoid Tumor	5
Spinal cord palsy	
Complete (Frankel A, B)	0
Incomplete (Frankel C, D)	1
None (Frankel E)	2
Total points	Predictive prognosis

0-8	<6 months
	≥6 months
	≥1 year

Tomita et al. (2001) developed a new scoring system by retrospectively reviewing 67 patients including those treated conservatively. Because items constituting the original Tokuhashi score were not differentially weighted, it was revised by weighting each factor of each item using the Cox proportional hazards model. It was simplified by excluding paralysis, which was not considered to affect the life prognosis. In addition, expected survival period and treatment selection including the indication for conservative therapy were specified in detail according to the total score: An expected survival period of 2 years or longer and en bloc excision for scores of 2-4, 1-2 years and debulking for scores of 4-6, 6-12 months and palliative decompression for scores of 6-8, and 3 months or less and terminal care for scores of 8-10. This scoring system, prepared in a surgical patient centered manner, is often used for the evaluation of surgical indications along with the Tokuhashi score, and its usefulness has been evaluated in many reports [12-15].

Table 2. Tomita Score (2001)

Prognostic Factors	Points
Primary tumor	1
Slow growth (breast, thyroid etc.)	2
Moderate growth (kidney, uterus, etc.)	4
Rapid growth (lung, stomach, etc.)	3
Visceral metastases Treatable Untreatable	4
Bone metastases Solitary or isolated	1
Multiple	2
Total Points 2-4	Predicted prognosis
06-08	>2 year
06-08	1-2 year
08-10	6-12 months
	<3 months

Patients with spinal metastasis who have good to moderate prognoses seem to benefit from more aggressive surgery. Although still palliative in nature, surgery for patients with good prognoses can be more aggressive (i.e., larger excision), and more instrumentation can be warranted. In addition, patients with acceptable prognoses (> 3 mo) can still benefit from surgery for symptom relief and mechanical stability, whereas those with poor prognoses should be treated conservatively without surgery [13].

Kumar et. al proposed guideline which categorizes patients with symptomatic metastatic bone disease into 2 neurological groups namely one with neural deficit and the other without and subcategorizes them according to the presence or absence of radiological features threatening neurology. Treatment protocol follows two pathways which those with neurological deficit and those without [14].

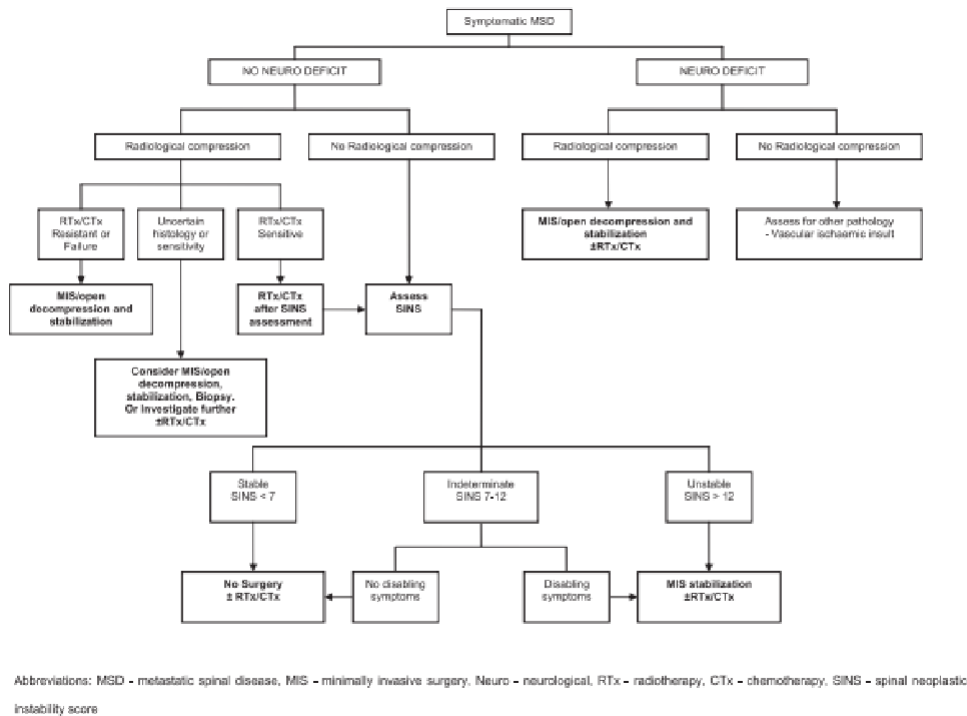


Figure 6. Algorithm for management of metastatic spinal disease

4. Conclusion

In our case, surgical techniques such as open decompression and stabilization are used from the condition of the patient who has a neurodeficit and compression from radiological examination with good prognosis. Corpectomy and laminectomy was used for the decompression techniques, while stabilization is performed in the posterior column.

5. Data Availability Statement

The datasets generated and analyzed during the current study are not publicly available due to privacy and ethical considerations but are available from the corresponding author upon reasonable request.

6. Ethical Statement

Sumatera Medical Journal (SUMEJ) is a peer-reviewed international electronic journal. The following statement clarifies the ethical behavior expected from all parties involved in the publication process of articles in Sumatera Medical Journal (SUMEJ), including authors, the Editor-in-Chief, the Editorial Board, peer reviewers, and the publisher, TALENTA Publisher Universitas Sumatera Utara. This statement is based on the Best Practice Guidelines for Journal Editors developed by Committee on Publication Ethics (COPE).

7. Author Contributions

All authors contributed to the design and implementation of the research, data analysis, and finalizing the manuscript.

8. Funding

No funding.

9. Acknowledgements

The authors would like to thank all parties who contributed to this study and supported the completion of this research.

10. Conflict of Interest

Authors declares no conflict of interest.

References

- [1] Van Goethem JW, Van den Hauwe L, Özsarlak Ö, De Schepper AM, Parizel PM. Spinal tumors. *European Journal of Radiology*. 2004;50(2):159-176. Available from: <https://doi.org/10.1016/j.ejrad.2003.12.006>.
- [2] Jayarangaiah A, Kemp AK, Kariyanna PT. Bone Metastasis. In: *StatPearls* [Internet]. StatPearls Publishing; 2022. Available from: <https://www.ncbi.nlm.nih.gov/books/NBK547754/>.
- [3] Wewel JT, O'Toole JE. Epidemiology of spinal cord and column tumors. *Neuro-Oncology Practice*. 2020;7(Suppl 1):i5-i9. Available from: <https://doi.org/10.1093/nop/npz045>.
- [4] Mossa-Basha M, Gerszten PC, Myrehaug S, Mayr NA, Yuh WT, Jabejdar Maralani P, et al. Spinal metastasis: diagnosis, management and follow-up. *The British Journal of Radiology*. 2019;92(1103):20190211. Available from: <https://doi.org/10.1259/bjr.20190211>.
- [5] Choi D, Crockard A, Bunger C, Harms J, Kawahara N, Mazel C, et al. Review of metastatic spine tumour classification and indications for surgery: the consensus statement of the Global Spine Tumour Study Group. *European Spine Journal*. 2010;19(2):215-222. Available from: <https://doi.org/10.1007/s00586-009-1252-x>.
- [6] Widiana IK, Irawan H. Clinical and Subtypes of Breast Cancer in Indonesia. *Asian Pacific Journal of Cancer Care*. 2020;5(4):281-285. Available from: <https://doi.org/10.31557/APJCC.2020.5.4.281-285>.
- [7] Sung H, Ferlay J, Siegel RL, Laversanne M, Soerjomataram I, Jemal A, et al. Global cancer statistics 2020: GLOBOCAN estimates of incidence and mortality worldwide for 36 cancers in 185 countries. *CA: A Cancer Journal for Clinicians*. 2021;71(3):209-249. Available from: <https://doi.org/10.3322/caac.21660>.
- [8] Chan-Seng E, Charissoux M, Larbi A, Tétreau R, Gerber YN, De Verbizier-Lonjon D, et al. Spinal metastases in breast cancer: single center experience. *World Neurosurgery*. 2014;82(6):1344-1350. Available from: <https://doi.org/10.1016/j.wneu.2014.07.014>.
- [9] Ciftdemir M, Kaya M, Selcuk E, Yalniz E. Tumors of the spine. *World Journal of Orthopedics*. 2016;7(2):109-116. Available from: <https://doi.org/10.5312/wjo.v7.i2.109>.
- [10] Kumar N, Tan WL, Wei W, Vellayappan BA. An overview of the tumors affecting the spine—inside to out. *Neuro-Oncology Practice*. 2020;7(Suppl 1):i10-i17. Available from: <https://doi.org/10.1093/nop/npz046>.
- [11] Donthineni R. Diagnosis and staging of spine tumors. *Orthopedic Clinics of North America*. 2009;40(1):1-7. Available from: <https://doi.org/10.1016/j.ocl.2008.10.002>.
- [12] Tokuhashi Y, Uei H, Oshima M. Classification and scoring systems for metastatic spine tumors: a literature review. *Spine Surgery and Related Research*. 2017;1(2):44-55. Available from: <https://doi.org/10.22603/ssrr.1.2016-0015>.
- [13] Aoude A, Amiot LP. A comparison of the modified Tokuhashi and Tomita scores in determining prognosis for patients afflicted with spinal metastasis. *Canadian Journal of Surgery*. 2014;57(3):188-193. Available from: <https://doi.org/10.1503/cjs.024812>.
- [14] Kumar N, Malhotra R, Zaw AS, Maharajan K, Naresh N, Kumar A, Vellayappan B. Evolution in treatment strategy for metastatic spine disease: presently evolving modalities. *European Journal of Surgical Oncology*. 2017;43(9):1784-1801. Available from: <https://doi.org/10.1016/j.ejso.2017.05.007>.
- [15] Barzilai O, Boriani S, Fisher CG, Sahgal A, Verlaan JJ, Gokaslan ZL, et al. Essential concepts for the management of metastatic spine disease: what the surgeon should know and practice. *Global Spine Journal*. 2019;9(1 Suppl):98S-107S. Available from: <https://doi.org/10.1177/2192568218800398>.